HC 4MLC 2

TUMOURS OF THE BLADDER

E. HURRY FENWICK

FASC. I.

Scudder.

FRONTISPIECE.

An extremely fleecy villous papilloma overhanging the right ureteral orifice, causing dilatation of the corresponding ureter (Norwich Museum).

TUMOURS OF THE BLADDER:

THEIR PATHOLOGY, DIAGNOSIS, AND TREATMENT.

BEING

THE JACKSONIAN PRIZE ESSAY OF 1887

(RE-WRITTEN),

WITH 200 ADDITIONAL CASES.

BY

E. HURRY FENWICK, F.R.C.S.,

SURGEON TO THE LONDON HOSPITAL; SURGEON AND PATHOLOGIST TO ST. PETER'S HOSPITAL FOR URINARY DISEASES; CONSULTING SURGEON TO THE WEST HERTS INFIRMARY.

LONDON

J. & A. CHURCHILL

7 GREAT MARLBOROUGH STREET

1897

17. F 60

BOSTON MEDICAL
FEB 15 1921
LIBRARY

TO MY FATHER,

DR. SAMUEL FENWICK,

WHO ADVISED AND ENCOURAGED ME IN 1884 TO COLLECT

THE PATHOLOGICAL MATERIALS FOR THIS WORK,

I DEDICATE THE RESULT AS A SLIGHT

TOKEN OF GRATITUDE AND AFFECTIONATE RESPECT.

Digitized by the Internet Archive
in 2025

https://archive.org/details/tumoursofbladder0000ehur

PREFACE.

The following pages embody an essay upon tumours of the bladder to which the Jacksonian Prize was awarded in 1887. The material for that essay had been collected between the years 1884 and 1887,—a period marked by startling changes in the operative treatment of all forms of urinary disease. The labours of Bigelow upon litholapaxy, of Sir Henry Thompson and Guyon upon tumours of the bladder, of Garson, Braune, and Petersen upon supra-pubic cystotomy, of Belfield and MacGill upon supra-pubic prostatectomy, and of Henry Morris upon the surgery of the kidney and ureter, had, in sweeping away old conservative procedures, supplied a large array of fresh and reliable facts for comparison and study. Operative technique had, indeed, made rapid and conspicuous progress; but diagnosis, prognosis, and, if I may add, sound judgment in the proper selection of the form of operation required by each individual case, still lagged far behind.

Two weeks after the essay had been submitted to the Council of the College of Surgeons, one of the first incandescent lamp cystoscopes, made by Leiter of Vienna, came into my possession; and I realised at once that the means for obtaining accuracy in diagnosis, in symptomology, and in prognosis had been at last secured. I had no doubt but that this method of examining the bladder with electric light, which we owe to the genius of Nitze, would render, *if expertly used*, the judicious treatment of most of the obscure diseases of the urinary tract possible. I considered that perhaps in no

disease would its influence be more surely felt than in the exact diagnosis of tumours of the bladder, and I determined to postpone the publication of the essay I had prepared until I had observed some fifty cases of the disease. But I soon found this number insufficient, and I waited until I had gained an experience of two hundred. Ten years elapsed before this object was attained; much of the original essay has had to be deleted, and much of it modified in the light of the knowledge obtained by the Nitze method, and by the corrections in the pathological sections. The pathological section has been revised and enriched by the labours of many workers. Since I first visited the museums the tidal wave of curatorial energy has swept away many of the older specimens and fresh ones have been substituted for them, the numbers have been changed, and the errors in the descriptions have been mostly corrected.

Mr. J. H. Targett, Curator of the College of Surgeons Museum, has been especially active in the re-examination of museum specimens, and it is mainly due to his willing and generous aid that I have been able to keep pace with the change. I have often had occasion to recognise the correctness of his microscopical diagnosis, for he has reported upon nearly all the tumours I have removed by operation, and the subsequent progress of the patient has usually tallied with his written prognosis. I can only regret that his contribution to the 'Transactions' of the Pathological Society upon vesical sarcoma has not yet issued from the press, and I have therefore been unable to read or to quote the pathological knowledge he has so laboriously acquired.

My thanks are due to Dr. Donald Day, of Norwich, for obtaining for me the frontispiece; to Dr. Pauly, jun., for permission to use the history of a remarkable specimen of myxoma of the adult bladder preserved in the Leipzig museum; and to my friend Dr. Thiersch for obtaining a correct drawing of the preparation. To Dr. Rundle, of Plymouth, I owe permission to photograph and reproduce his specimen of epithelioma of the ureter (fig. 11, p. 17, fasc. i).

To Dr. Albarran, of Paris, I am indebted for leave to reproduce three illustrations from his valuable monograph on 'Tumours of the Bladder.'

I mention with keen appreciation the courtesy and help I received in collecting material for the original essay. The authorities of the various museums both at home and abroad permitted me to examine, describe, sketch, or photograph the collections without reserve. Some of the photographs I have used have been skilfully made for me by Dr. Bousfield.

The Council of the College of Surgeons have kindly granted me permission to publish the Jacksonian Prize Essay.

Lastly, to those of my colleagues at the London and St. Peter's Hospitals who have so generously permitted me to examine and record their cases, and to all those who have so cheerfully kept me *en rapport* with the progress of the patients they have sent to me with symptoms of vesical growth, I tender my very sincere and appreciative thanks.

E. HURRY FENWICK.

14, Savile Row, W.;
January, 1897.

BOSTON MEDICAL
FEB 1 5 1921
LIBRARY

CHAPTER I.

PRELIMINARY CONSIDERATIONS.

Finding that the macroscopy of bladder growths was somewhat confusedly treated by most writers on the subject, and the very limited experience of one observer was merely added to the written labours of his predecessors,* I determined in 1884 to examine the various museums, and to build up reliable statistics of the appearance, position, size, and method of invasion of the various tumours of the bladder. This was before the introduction of the incandescent light cystoscope, at a time when gross appearances of vesical tumours could only be obtained by examination of museum specimens, or by the then rare operation of supra-pubic cystotomy.

I visited most of the museums of England, Scotland, Ireland, Germany, France, Belgium, Holland, Denmark, Norway, Sweden, Austria, Hungary, and Switzerland.† Some of the museums in the towns and universities of these lands were rich; in others the collection was being removed (Lyons, Bonn, Hamburg). In one the collection was kept locked—Copenhagen. In some no vesical neoplasms were included—Upsala, Christiania, Newcastle-on-Tyne (Durham University). In some the collections were so arranged in bottles that no sketch or accurate description could be obtained; and though useful in formulating and increasing my experience of the size and appearance of the growths, the information derived from such sources could not be included in the tables I constructed. For various reasons fifty

* Take, for example, M. Féré's able and solid work on 'Cancer of the Bladder.' Frequent quotations from his statistics upon the site of cancerous growths in the bladder occur in the literature. M. Féré massed together 107 facts concerning the position of the growths in the bladder, and taking "tumeurs cancereuses ou villeuses" together, he evolves a table that is quoted for every form of growth—benign, intermediate, or malignant.

† My travels in Italy, Sicily, Spain, and Portugal showed me the futility of seeking material in these lands.

specimens were discarded; these were in the collections of Berlin, Leipzig, Halle, Dresden, Prague, Vienna, Heidelberg, Brussels, Stockholm, and Kiel.

For the purpose of noting the exact position of each vesical growth I was forced to divide the bladder into three divisions, each formed of about one third of the cavity of that viscus. These may be termed *zones.**

The upper zone embraces the apex; the lower zone the base; the middle zone the intermediate region.

The lower zone has the following boundaries:—If a line be drawn from an inch above the ureteral orifices, around the bladder, and at right angles to its longest diameter, it will pass above the urethral orifice. The lower zone consequently embraces both the ureteral orifices, the trigone, the urethral orifice, and the narrow sections of the adjoining parts of the anterior, of the lateral, and of the posterior walls, which surround and abut on these well-defined positions.

The rest of the bladder is divided equally into the upper and middle zones (*vide* Fig. 1).

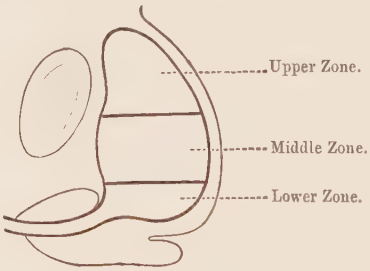

Fig. 1.

These zones are further divided by the anterior, lateral, and posterior walls, so that in describing any part of the bladder an appropriate name for the area in question is obtained.

Growths† or tumours of the bladder may be divided for the sake of clearness into three groups, namely:—

1. Those which involve the bladder by contiguity (invasion).

* Writing four years subsequent to this essay, M. Albarran adopts nearly the same method of dividing the bladder, and each original investigator of vesical disease encounters the same difficulty, and constructs a somewhat similar plan of division (*vide* Kelly, 'Nineteenth Century of Medicine,' p. 668).

† It is idle to make a severe distinction between "growths" and "tumours," and to retain only those which form as prominent swellings. The term "tumour" has been adopted quite irrespective of the macroscopy, as being in consonance with the general acceptation of a new growth.

2. Those which occur in the bladder as secondary foci (metastatically).

3. Those which originate in the tissues of the bladder (primary tumours).

There is but little surgical interest attaching to those malignant growths which affect the bladder either by invasion or by metastasis; and although this monograph concerns itself mainly with "primary" growths of the bladder, yet a brief consideration of the external sources whence the bladder may be affected by growth is important for the purposes of rendering the sections upon diagnosis, prognosis, and treatment more complete. Moreover, much confusion will be avoided if such invading and metastatic growths are referred to, before those tumours which have their origin in the bladder are dealt with.

1. *Malignant Growth affecting the Bladder by Contiguity (Invading Growth).*

Growths implicate the bladder by extension from (A) the prostate and seminal vesicle, (B) the ureter, (C) the rectum or the sigmoid flexure, (D) the peritoneum and subperitoneal tissue, (E) the abdominal wall, (F) the periosteum of the pelvis, pubes, and spine, (G) the penis; and in the female, in addition to most of these sources, from (H) the vagina, the uterus and its annexes.

(A) *Invasion of the Bladder by Malignant Growth of the Prostate.*

The chief external source of the invading growths in the male is the prostate.* Much difficulty is encountered, not only macroscopically, but also microscopically, in deciding whether certain malignant trigonal growths spring from the subjacent prostate or from the trigonal tissues.† This statement is supported by an examination of any large museum; for in most, isolated examples of the invasion of the bladder from a prostatic source are to be encountered, classified as "tumours of the bladder." The literature is by no means free from such errors, and it is a knowledge of this defect which prevents most of the more recent authors accepting as

* Klebs ('Handbuch der pathologischen Anatomie,' Berlin, 1870, Lief iii) holds that all bladder carcinomata have a prostatic origin, a view that is, at the present day, quite untenable.

† Kuster, "Primary Prostatic and Primary Vesical Carcinoma cannot as a Rule be sharply differentiated," 'Archiv klin. Chirurg.,' 1891, Heft 4, p. 865.

correct the accumulated statistics which have been loosely compiled from all sources.

In the collection at Berne (quoted by Socin *) there is a specimen of an adeno-carcinoma (Klebs) of the prostate, and although it has infiltrated the muscular walls and mucous membrane of the adjoining urethra and bladder, yet part of it projects as a small pedunculated tumour, the size of a walnut, from the trigone (Fig. 2). A superficial observer,

Fig. 2.—Adeno-carcinoma of the prostate† (Berne Museum); left half of bladder longitudinally bisected. The prostatic carcinoma and its polypoid projection have been more clearly demonstrated by an oblique section through the growth.

even an inexperienced operator, might easily have mistaken this pedicled growth for a primary bladder tumour.

Apparently a very similar case is reported in the journals by Dr. J. H. Neale,‡ under the title of an "Adeno-encephaloid Cancer of the Bladder;" but the position, microscopy, and

* Socin, 'Die Krankheiten der Prostata,' p. 108.
† Copied from Socin, figure on p. 108.
‡ 'Brit. Med. Journ.,' May 21st, 1887.

clinical course of the case points to a prostatic rather than to a vesical origin.

The microscopical difficulty of determining the origin of growth at the bladder base is well illustrated by a case of Marchand's.* A growth projecting into the bladder at some distance from the prostate was proved to be in direct connection with that gland by means of long canals filled with epithelial structures, something like the far-reaching roots of a tree.

The Character of the Invasion of Carcinomatous Prostatic Growths.

It is very rare, I believe, for the softer form of prostatic carcinoma to break into the bladder; more commonly it is the very hard infiltrating variety which gradually involves the prostatic urethra and trigone.†

There are three varieties of carcinomatous invasion. The following cases, taken from a series of thirty-two of which I have notes, will serve to illustrate.

(*a*) *Malignant Growth of the Prostate fungating through the Trigone.*

On opening the bladder of a man æt. 60, dying ostensibly from malignant disease of the bladder and secondary growths in the abdomen, a large cauliflower growth was seen to occupy the neck of the viscus, and to extend to the left ureteral orifice, which had become involved and rendered impervious. A vertical section showed the growth to spring from that part of the prostate which was immediately beneath the trigone. The cauliflower growth was composed of the confluence of distinct masses, which were breaking down and had formed a ragged fungating crateriform ulcer. The bladder was hypertrophied; the left ureter was dilated above the throttling ring of growth. The liver was much enlarged, weighing 10 lbs., and contained masses of secondary growths. The abdominal glands were also enormously enlarged. I am indebted to Dr. Scanes Spicer for this specimen.

* Marchand, "Ein Beitrag zur Casuistik der Blasentumoren," 'Langenbeck's Archiv,' xxii, 1878.

† Compare Author's 'Cardinal Symptoms,' p. 191, remarks on fifteen cases; two thirds of the prostatic carcinomata under my care have broken into the bladder.

(*b*) *Prostatic Carcinoma forming Hard Secondary Deposits in Prostatic Urethra and Adjoining Trigone.**

A patient æt. 56 was sent to me in 1890, by Mr. F. Meade Corner, for irritability of bladder. I found that he was suffering from carcinoma of the prostate of the hard variety, and I watched his progress through a typical course of this disorder for two years. On post-mortem I found the bladder was healthy except at the base (inferior zone). The surface of the orifice of the bladder was irregular from the projection of yellowish hard nodules of carcinoma. These were neither confluent nor ulcerated. They were like clumps of melted yellow wax, and they varied in size from a split pea to a bean. The same condition existed in the prostatic urethra. The prostate both cut and cupped like a scirrhous mamma. Microscopically it proved to be carcinoma of the glandular type (Targett).

(*c*) *Pre-urethral Prostatic Carcinoma invading Anterior Wall of Bladder.*

It was, perhaps, unrecognised before Croft pointed out the fact in 1868 that that portion of the prostate which is placed anterior to the prostatic urethra may degenerate into carcinoma, and affect the anterior wall of the bladder. The peculiarity of the invasion seems to consist not in the formation of a mound or of heaped-up nodular growths, but in an uniform and extensive infiltration of the anterior wall of the bladder. In the English museums I have seen carcinoma of the anterior wall, the prostatic origin of which was undoubted, labelled as "Vesical Carcinoma."

There is, then, a difference in the appearance and manner of the invasion of the bladder from the two parts of the prostate; and this difference may be due to the character of the structures which adjoin or abut upon the two portions respectively, *i. e.* upon the pre- and the post-urethral. *Non-resistent muscle* planes feebly check the infiltrations of growth from the former, whilst the *dense resistent* structure of the trigone opposes the invasion of infiltration from the latter position.

I have seen three examples. One occurred in an old gentleman of 86, who was sent to me by Dr. W. J. H.

* Cf. 487, Univ. Coll. Hosp. Museum; 103, Munich Museum; 1383, Edinburgh Museum; 211A, Berlin; 18 and 249, Vienna; 26, Neckar, Paris.

Wood, of Boston. He complained of symptoms of stone, and referred his pain to the suspensory ligament of the penis. He died very suddenly, and on post-mortem the anterior wall of the bladder was found to be infiltrated with carcinoma, and that part of the prostate which was in front of the urethra was the seat of similar disease. The remainder of the bladder and prostate were unaffected (Fig. 3).

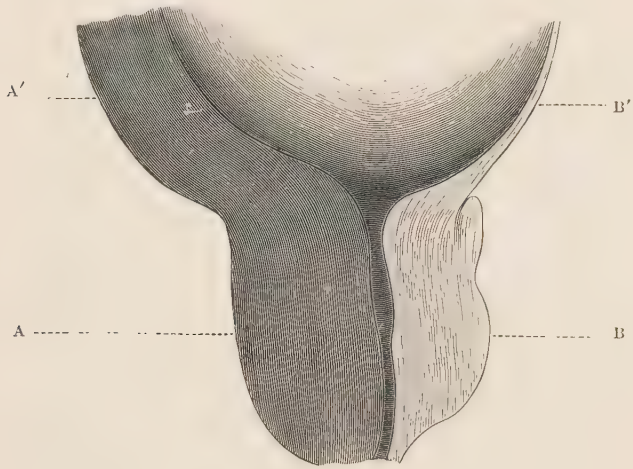

Fig. 3.—Vertical section of vesical orifice. Carcinoma of the pre-urethral part of the prostate invading the bladder along the anterior wall. A. Cancerous anterior (pre-urethral) part of prostate. A′. Invaded adjoining anterior wall of bladder. B. healthy posterior (post-urethral) prostate. B′ Healthy adjoining base of bladder.

Croft* records the following:—"A patient æt. 42 died of pyæmia of urinary origin. Bladder was greatly hypertrophied; its internal surface was rugose, and its lining membrane thickened, dark, and coated with phosphates. The anterior portion in the region of the upper two thirds of the prostate was ragged and villous from the disintegration of prostatic cancer. On cutting through the median line of the prostate above the urethra, a white, moderately dense tumour was divided; this was limited in each direction by the boundaries of the prostate. Except posteriorly, where it had invaded the anterior wall of the bladder, and where its disintegration had given rise to a villous appearance, the posterior parts of the prostate, *i. e.* below the urethra, were not involved in the disease."

* Croft, 'Path. Trans.,' vol. xix, p. 285.

The Character of the Invasion of the Bladder by Sarcoma of the Prostate.

Sarcoma of the prostate in youth* certainly possesses a tendency to cause multiple fleshy sarcomatous growths to develop about the bladder base,† even in the prostatic urethra; but, as far as my experience goes, these polypoid outrunners are by no means constant, and the vesical tumour may be single and very large. Moreover, as age advances the

FIG. 4.—The bladder is laid open longitudinally, and occupies the upper half of the picture; the lower half is composed of the longitudinally bisected prostatic sarcoma: a glass tube marks the prostatic urethra. The polypoid growths are best seen to the right of the middle of the picture (Guy's Museum).

prostatic sarcoma loses this peculiarity in proportion as its luxuriance and rapidity of growth decline.

In Guy's Hospital Museum, 2104[32] (Fig. 4), there is a

* Half of the cases occur before eight years of age.

† Sarcoma of the vagina often exhibits the same proclivities.

specimen of a sarcomatous prostate which has invaded the bladder; it was removed from a boy, æt. 2, who had been under Mr. Hilton's care in 1858. Polypi are seen springing from the neck by slender peduncles. The prostate is large —almost as the bladder (a bougie has been placed in the prostatic urethra), and the growth which has infiltrated it is firm and fleshy.

A more recent and excellent specimen of myxo-sarcoma of the prostate invading the bladder is recorded by Mr. Spanton* and Mr. Targett.

A boy æt. 5 was admitted under Mr. Spanton for great difficulty in urination, which had existed for one month. There was no hæmaturia. A large tumour, the size of a man's fist, was felt *per rectum*, after the bladder had been emptied by an aspirator. It proved to be a growth of the prostate gland which had displaced the bladder upwards to the umbilicus, and had rendered the urethra impervious.

Fig. 5.—Myxo-sarcoma of a boy's prostate, with outrunners around vesical orifice (R.C.S. Museum).

The boy died in thirteen weeks. At the autopsy the tumour was found to occupy the greater part of the pelvic cavity, and to have invaded the ischio-rectal fossæ obstructing the rectum.

The bladder, Fig. 5 (R.C.S. Museum, 4360c), is displayed

* 'Path. Trans.,' vol. xlii, p. 218.

opened from behind. Attached to its anterior wall is a portion of a large tumour which probably developed in connection with the prostate gland. It is soft and gelatinous in consistency. Within the bladder there are numerous soft polypi, closely packed together around the internal meatus of the urethra. The orifice of the right ureter is free. Histologically the tumour is a myxo-sarcoma, and the polypi of the bladder are composed of a similar growth covered with normal mucous membrane.

The enormous extent to which prostatic sarcoma may develop in the child is well shown in a specimen (Fig. 6) which is in the collection at Berne,* and which Professor Socin has described. It serves also to illustrate the polypoid outrunners to which I am alluding. A boy 8 months old had suffered from retention, and catheterism was extremely difficult. He died of cysto-pyelitis. On post-

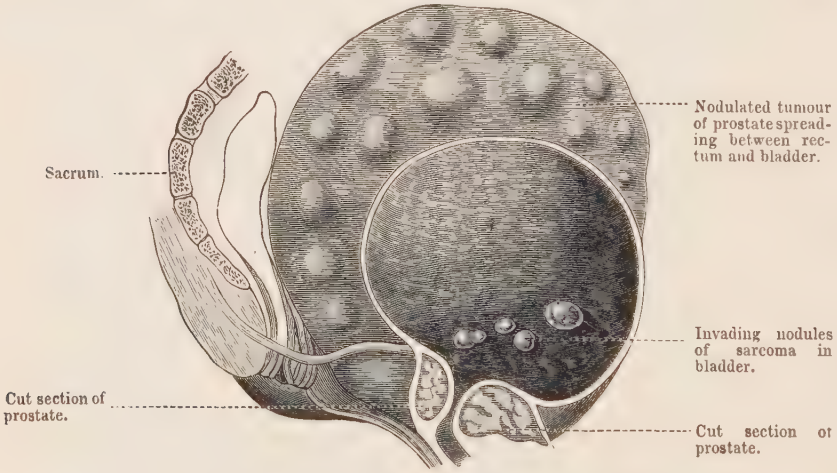

Fig. 6.—Enormous prostatic sarcoma in a baby (Socin).

mortem both ureters were found enormously dilated, and a child's-head sized prostatic growth, which had grown mostly between the bladder and rectum, was discovered filling the entire pelvic cavity. It did not lie quite centrally, but had grown more to the left; thus the commencement of the urethra had been thrust sharply to the right, and a right-angled bend had been created, which had caused the difficulty in instrumentation. It is noticeable that the growth seems also to have affected that part of the prostate which lies anterior to the urethra.

* From Socin, 'Die Krankheiten der Prostata,' p. 107.

In the case of a man æt. 21, recorded by West,* a small round- and spindle-celled sarcomatous prostate, the size of a large orange, had invaded the bladder. A fleshy polypus 2 inches long was found attached by a long narrow pedicle to the neck of the bladder. Another large oblong mass, $2\frac{1}{2}$ inches long, arose from the side of the trigone of the bladder, several small pedunculated similar masses taking origin from various adjacent parts.

In contrast to the above I may mention the case of a gentleman æt. 61, who applied to me with the diagnosis of stone in the bladder, but in whom I detected a large sarcoma of the prostate. The whole of the prostate (R.C.S. Mus., 4360 B) was involved. It was much elongated antero-posteriorly, and measured $2\frac{1}{2}$ inches in length in that direction. The growth projected upwards into the neck of the bladder, and formed a rolled collar around the commencement of the urethra. Large masses also projected from the prostate on each side of the bladder and rectum,

Fig. 7.—Longitudinal section of the sarcomatous outgrowth from the median lobe of the prostate (Socin).

but the latter canal was not involved. The tumour was a very small round-celled sarcoma, a few large round cells only being noticeable (Targett).

Sarcoma springing from the median lobe of the prostate is, I believe, a rare occurrence. Socin figures a very remarkable case of this kind which is taken from a man æt. 51

* 'Path. Trans.,' vol. xxxiv, 1883, p. 145.

(Fig. 7).* Slightly to the left of the orifice there rose a longish oval, hen's-egg shaped, broadly pedunculated tumour. Its base was strong, hard, and could only be cut with a saw. The upper part was soft, and ulcerated on the surface. It sprang from the "pars intermedia prostatæ."

Carcinoma of a Vesicula Seminalis invading Bladder.

I have only met with one example † in my work in which I could definitely trace the invasion of the bladder from a seminal vesicle. This occurred in a man æt. 59, who first presented symptoms of overflow due to an "engorged bladder," accompanied by hematuria. He died after repeated and profuse hæmorrhage from the bladder, and on cutting into the bladder I found the anterior wall thick and hypertrophied, the cavity contracted, and the mucous membrane, with the exception of the part next to be described, healthy. The left half or two thirds of the trigone, and the part surrounding the left ureteral orifice, had been transformed into a flat hard patch of carcinomatous growth. It formed a shallow cupped ulcer, with an uneven, sloughy, nodulated base. This patch was so suggestive of invasion by contiguity from the back of the bladder, that the latter was examined. At the junction of the left vesicula seminalis and the left lobe of the prostate, and involving *both*, was a hard carcinomatous infiltration. Microscopically the growth was found to be of the ordinary type, and to have originated at the junction, so that both the prostatic lobe and the vesicula seminalis were equally and thoroughly involved. The wave of infiltration had then seemingly passed towards the vesical cavity. The left ureter was plugged and surrounded by the growth.‡

(B) *Malignant Growth affecting the Bladder by way of the Ureter.*

The implication of the bladder by way of the ureter is apparently carried out by two paths; either the urine carries from the malignant kidney scraps of growth and blood, which become implanted on the vesical mucous

* Socin, loc. cit., p. 110, fig. 33.

† 'Path. Trans.,' vol. xxviii, 1887, p. 199.

‡ The man died very rapidly, after the removal of the residual urine, by profuse hæmaturia, which may account for so very localised a patch. I have met with an exactly similar preparation in Dresden, No. 249, Hospital Collection, date 1858.

membrane, or the ureteral walls become infiltrated, and the disease spreads downwards until it diffuses itself in the parietes of the corresponding half of the bladder. Judging from the few cases we have at command, it would seem that renal carcinomata rather possess the power of evoking villous tufts in the bladder, whilst the sarcomata infect or implant themselves on the surface of the mucous membrane.

(*a*) *Implication by the Urine Stream.*

Such cases are apparently rare. In St. George's Hospital Museum (42 c) there is a specimen taken from a case in which an enormous renal encephaloid tumour, weighing 15½ lbs., had extended down the ureter. The upper end of the ureter was found filled with growth and blood-clot. This block had passed the entire way down the ureter, and projected into the bladder in the form of an elongated growth, somewhat like a large bougie placed in the ureter to mark the orifice. It was covered with sabulous deposit, and did not seem as yet to have infected the vesical (contiguous) wall.

Curiously enough, another and somewhat similar case has occurred lately at St. George's Hospital, under the care of Mr. Bennett.*

R. W—, æt. 52, began suddenly to have dysuria, and after seven weeks he passed a long cast of coagulated blood and sarcomatous cells, six inches long. He died four months after the onset of the bladder difficulty, and a large left renal sarcoma (large round-celled), weighing 6 lbs. 2 oz., was found. The left ureter was enlarged; the bladder was enlarged, and lying loose in its cavity was a small fleshy mass of sarcoma, about the size of a hazel-nut. It was encrusted with phosphates. At the left side of the trigone there was a small villus-covered growth (Fig. 8). The vesical growth was probably implanted by the deposit from the left renal mass.

A gentleman æt. 62 was sent me by Dr. Justin Douglas, of Bournemouth, with profuse hæmaturia. He was glycosuric. With the cystoscope I saw dangling from the right ureteral orifice a thick piece of clot and growth. I sucked this away. He died nine months later with obvious carcinoma of the right kidney.

It is interesting to note that cases are on record † in which *benign growths of the bladder* were found in renal or ureteral

* Penrose, "Sarcoma of Kidney with Loose Masses in the Bladder," 'Path. Trans.,' vol. xliv, 1893, p. 96.

† Murchison, 'Path. Trans.,' vol. xxi, p. 241.

carcinoma, as if the seedlings from an upper source had become implanted on a healthy vesical surface.*

The following case occurred in my own practice:—A gentleman æt. 43 was sent to me by Dr. H. H. Taylor, of Brighton, with hæmaturia. On cystoscopy I discovered and

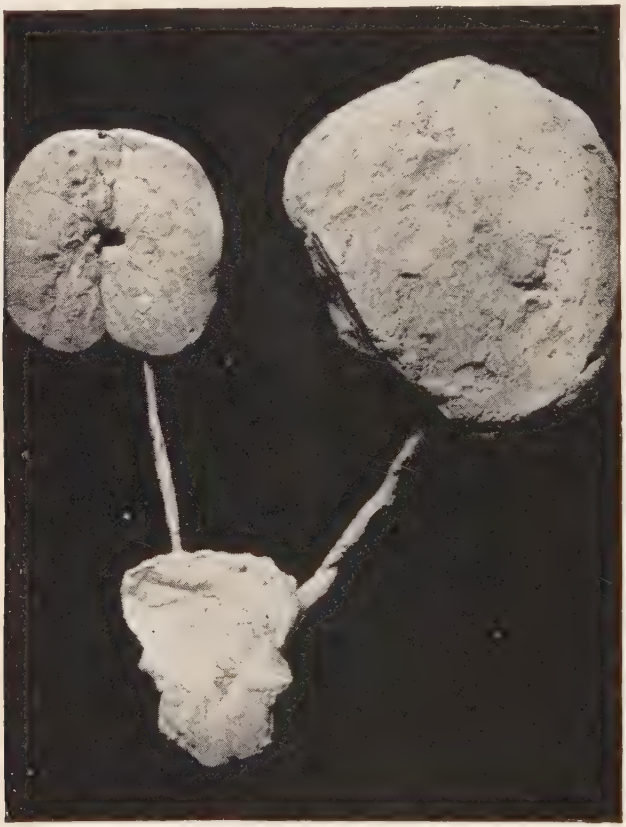

FIG. 8.—Kidneys, ureters, and bladder are shown. The bladder has been laid open longitudinally, and the villous-covered growth may be dimly seen at the left side of the trigone. The sarcoma of the left kidney contrasts well with the normal right kidney (St. George's Museum, Ser. xi, 31 F).

removed a perfectly pure villous papilloma from the right ureteral orifice. A year later he began to suffer pain in the right kidney, and was operated on by Mr. Knowsley Thornton, under the belief that he had renal calculus. The right kidney was found to be carcinomatous. It was

* Roberts, 'Bull. gén. de thér.,' 1877, p. 301; Clarke, 'Med. Times and Gazette,' 1860, p. 154, vol. ii; Mengalde, 'Gaz. Méd.,' Paris, 1840, p. 92; Kuster, loc. cit.; Albarran, p. 416.

removed, and the patient died uræmic. On reviewing his symptoms I see that the renal carcinoma probably antedated the vesical papilloma.

The best instance of this class of disease with which I am acquainted was shown at the Pathological Society, January 5th, 1897, by Dr. Douglas Drew. The patient, a man æt. 56, had suffered from left renal colic and profuse hæmaturia for $3\frac{1}{2}$ years. Nephrotomy revealed no calculus. The wound remained open. After death the left kidney was found to be hydronephrotic, and its pelvis was covered with malignant villous growth. The left ureter was splashed in its entire extent by small sessile masses of pure villous papilloma. At the vesical orifice of the left ureter was a large walnut-sized pure villous papilloma.

(*b*) *Invasion of the Bladder by Disease spreading along Ureteral Wall.*

The bladder can, however, be reached by implication of the ureteral walls. Thus Mr. Targett* records the following unusual and interesting case:

A man æt. 46 was admitted to a hospital for hæmaturia and wasting. His illness began four months previously

Fig. 9 (Targett's case).—Bladder laid open longitudinally. The stump of the right ureter is enlarged with sarcoma, and the growth extends into the bladder through the right ureteral orifice. It is marked with a glass rod.

with severe pains in the loins and thighs. A large tumour occupied the umbilical and right lumbar regions of the

* Targett, 'Path. Trans.,' vol. xliii.

abdomen, and the urine contained blood and sarcomatous cells. The patient became extremely emaciated, and died five weeks after admission. At the autopsy the tumour was found to be situated behind the duodenum and pancreas. It had extended down the spinal column as far as the brim of the pelvis, and had surrounded the large vessels together with the right ureter, the whole length of which was filled with growth. On cutting into the urinary bladder, Fig. 9 (R.C.S., 3706A), a polypoid tumour was found, the size of a cherry, attached to the orifice of the right ureter. The pedicle of the tumour was covered with healthy mucous membrane, but at its summit around the termination of the ureter the surface was ulcerated. On dissecting the back of the bladder the much enlarged lower end of the right ureter was seen. Its calibre was distended with a soft white growth, continuous with that inside the bladder.* Histologically it is a round-celled sarcoma.

Fig. 10† represents an oblong block of the abdominal tumour removed from this case. The right ureter (C) is seen to be entirely surrounded with a soft spongy new growth, and its calibre, which measured nearly half an inch in diameter, is

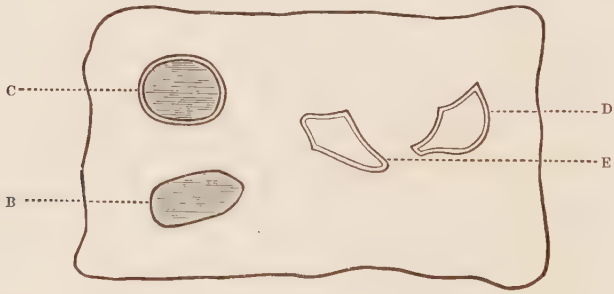

FIG. 10.—Oblong mass of growth embedding ureter and vessels.

depicted distended with a similar material. The adjacent common iliac arteries (D, E) are also embedded in the tumour, but they are patent. Immediately beneath the ureter is seen a large vein, probably the right common iliac (B), the canal of which is filled with a thrombus.

Somewhat similar to this specimen, but probably in a less advanced stage, is one exhibited by Mr. Rundle at the Pathological Society, November 20th, 1895 (Fig. 11). The lower third of the right ureter is infiltrated by a dense primary

* R.C.S. Museum, 3706A.
† Copied from R.C.S. Museum, 3706B.

carcinomatous growth,* which has produced hydronephrosis of the corresponding kidney. The vesical orifice of this

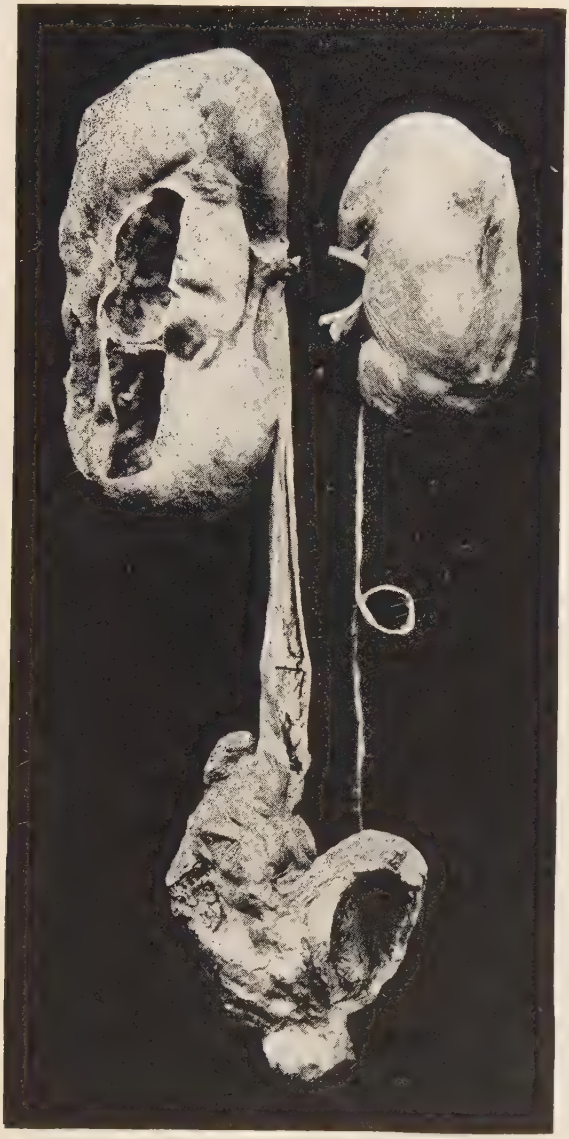

Fig. 11.—The lower third of the right ureter transformed into epithelioma. It has blocked the right kidney, and has produced a ring of polypoid growth at the right ureteral orifice. (Rundle's case.)

ureter is surrounded by a ring of small polypoid excrescences, the exact nature of which has not been determined.

* The existence of primary ureteral carcinoma was demonstrated by a specimen shown by Dr. Voelcker, 'Path. Trans.,' vol. xlvi, p. 133.

The vesical implication by downward growth must be distinguished from upward growth from a vesical source, instances of which have occurred in my practice, an example of which may be found in the 'Pathological Transactions,' vol. xviii, p. 159. The remarkable specimen in Westminster Hospital Museum, No. 850 (Figs. 12 and 13), may either be the upward extension of a growth commencing

Fig. 12.—Bladder laid open longitudinally. Passing through the infiltrated left ureter, bladder, and urethra is a thick bougie. The vesical mass around the instrument is epitheliomatous in its nature. (Westminster Museum.)

at the very orifice of the ureter, or primary ureteral epithelioma affecting the bladder by contiguity.

The bladder is seen laid open in front. Traversing the left ureter, bladder, and urethra is a piece of bougie. The vesical orifice of the left ureter is occupied by a large epitheliomatous growth, which invades the ureteral walls. On turning the specimen round (Fig. 13), the enormously

thickened ureter is seen lying on the bladder. Mr. Macleod Yearsley, who examined the specimen for me, reports that the infiltration is a true epithelioma, and that it has the character

FIG. 13.—Left side view of Fig. 12, to show infiltrated left ureter. (Westminster Museum.)

of the ureteral mucous membrane. The supposition is, therefore, that it started as a primary growth, and invaded the bladder by contiguity.

(C) *Carcinoma involving the Bladder by Extension from the Rectum or Sigmoid.*

This line of invasion is almost as rare as the implication of the prostate by the extension of a rectal carcinoma. I have met with various examples (*vide* Symptomatology).

Mr. P—, æt. 45, a patient of Dr. de Gruyther, was seen

in consultation with Dr. Carmalt Jones, and was kindly referred to me in April, 1888, by the latter for cystoscopic examination. His case was as follows:

In the summer of 1887 he had a sudden and severe attack of colic, diarrhœa, and vomiting. After the cessation of these symptoms, attacks of diarrhœa became habitual. He soon noticed that his urine issued in a bubbling, whistling manner. The water then became thick and foul, and finally he passed nearly a pint of blood and water. He was sounded by Dr. Carmalt Jones, and a growth or "a something" was detected with the beak, but no stone. The patient then commenced to pass quantities of colloid substance of a yellowish-brown colour, which soon became mixed with pieces of growth. These were examined microscopically, and the diagnosis of vesical growth was confirmed. He had frequency every hour, but no pain. His urine was fœtid, murky, and the stream finished with blood. I examined him with the cystoscope in April, 1888, and reported that he had a multilobed gelatinous-looking tumour springing from the posterior wall. Bimanual examination allowed me to distinguish a small Tangerine-sized tumour, apparently gluing the gut and the back of the bladder together. He continued passing pieces of growth until August 10th, 1888, when he was suddenly seized with an excruciating pain over the lower part of the belly (evidently peritonitis). I was unfortunately away on my holiday, but the patient was sent to the Cancer Hospital under the care of Mr. Elam, to whose courtesy I am indebted for permission to be present at and to quote the autopsy. On opening the body a large supra-pubic extra-peritoneal abscess was found. It was full of liquid pus, necrotic tissue, and urine. It communicated by two ragged holes (*a*, *b*, Fig. 14) with a second sac springing from the apex and back of the bladder. This second sac was full of necrotic growth, which had sprouted into both gut and bladder. The bladder was found small and contracted; the trigone was quite free, but sprouting from the middle zone of the posterior wall was a Tangerine-sized, deeply cleft, shaggy growth (*c*, Fig. 14). On making a vertical section through the enucleated pelvic viscera, it was seen that the bladder growth was the vesical end of a large mass which lay between the rectum and bladder, involving both cavities and firmly gluing both viscera together. The portion which had sprouted into and had encroached upon the lumen of the rectum was much larger and much more broken down than the vesical funga-

tion. Mr. D'Arcy Power,* who reported upon the microscopy of the growth, proved it to be a carcinoma, "but both cells and

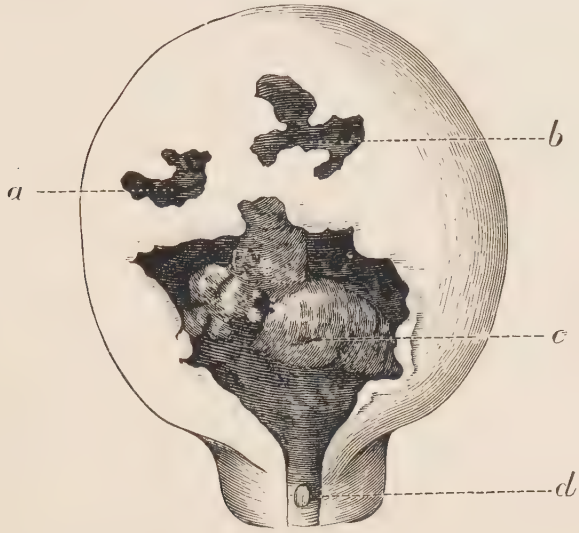

FIG. 14.—Bladder laid open longitudinally. Growths shown on the posterior wall, *c*; two ragged holes, *a b*, mark the site of the extravasation into the pre-vesical area.

stroma are undergoing an early stage of colloid and mucoid degeneration."

A gentleman of 60 was brought to me by Dr. Owen Taylor of Nottingham. The onset symptom was an attack of intestinal obstruction, after which fæces and gas were passed with the urine, and recurrent attacks of cystitis were complained of. Laparotomy confirmed the diagnosis of growth of the sigmoid or of the first part of the rectum, breaking into the bladder, and inguinal colotomy was performed by Dr. Taylor with benefit to the patient.

A similar case has been lately recorded by Dr. Heuston of Dublin.† Laparotomy was performed, the vesical opening refreshed and sutured, and the three inches of the sigmoid which was found to be affected by columnar epithelioma was resected. The patient unfortunately died on the fourth day with all the evidence of collapse. The post-mortem showed the sutured bowel and bladder firmly united. There was no peritonitis.

* Author, 'Elect. Illum.,' 2nd edit., p. 185.

† Heuston, "Entero-vesical Fistula treated by Laparo-enterectomy," 'Brit. Med. Journ.,' Feb. 24th, 1894, p. 405.

Usually intestinal symptoms precede those of cystitis (*vide* Symptomatology).

Examples from my post-mortem note-book.* "J. C—, æt. 65. Eleven years ago had obstinate constipation and great pain for seven months in belly about umbilicus, relieved by purgatives. Suddenly he 'felt something give way' (gall-stone into colon, stone expelled). Suffered from tapeworms eight years. Fourteen months before death when straining at stool urine came mixed with motion. Mass felt *per rectum*. Bladder and rectum communicatng. Diarrhœa and blood in stools. Exhaustion, death. P.M.—Soft carcinoma of rectum and bladder; large communication between cavities. Left ureter blocked."

"Body of a male æt. 54. Sigmoid flexure is attached to bladder at its posterior surface, there is a free passage between the two viscera. Bladder is much thickened, and around site of communication as well as in its cavity there is much deposit of carcinoma. There are tubercular deposits in lungs."

Féré ('Cancer de la vessie,' p. 13) quotes a case of Dr. Ollivier. Female æt. 67, of a phthisical history. "The first curve of the sigmoid was occupied by a soft mass, whose breadth was 1 to $1\frac{1}{2}$ inches. The gut was contracted at the site of the growth, and it had perforated the bladder at its posterior superior part. This communication was narrowed by cancerous nodules."

Nussbaum of Munich ("Die Operatione des Blasen Mastdarmkrebs," 'Schmidt's Jahrb.,' 1864, Bd. cxxi, p. 204) reports two cases where the rectal carcinoma propagated itself to the bladder, and upon which he had operated with success. Nobiling has a similar one ('Schmidt's Jahrb.,' 873, Bd. clx, p. 80).

(D) *Carcinoma of the Bladder propagated from the Peritoneum, &c.*

The only definite case I have seen is the following:—E. S—, æt. 58. On opening the body it was seen that the entire surface of the omentum had changed its character. It was much reduced in volume, greatly crumpled, and transformed into a thickish mass covered with innumerable pea-sized deposits of "colloid" cancer. It formed a short, thick apron, dependent from the lower margin of the stomach. The pyloric

* Many of the cases in this record have been observed at the London Hospital.

end of that viscus was transformed into a dense colloid mass which did not entrench upon the duodenum. The entire peritoneum, visceral and parietal, was covered with pea to bean sized clumps of brown or pinkish gelatinous cancer. The pelvis had a large fist-sized mass in the recto-vesical pouch. This had invaded the bladder through its posterior wall. No secondary deposits were found in any viscera.

Dr. O'Connor * quotes a somewhat similar case.

H—, æt. 78. On the external surface of the ascending colon nodules of colloid cancer of a plum colour were found, many of them as large as full-sized walnuts. The rectum was pressed upon by a large mass of the same cancerous formation. The bladder was the size of a child's head, and completely filled with cancerous growth. It did not contain any urine. There were secondary deposits in many organs. The first symptoms were intestinal.

Note on Sarcoma of Subperitoneal Tissue.

It is to be noted that sarcoma originating beneath the peritoneum at the apex does not appear very prone to affect the bladder by contiguity.

In St. Bartholomew's Hospital Museum, Specimen 2430 shows two walnut-sized sarcomatous growths at apex of a female child's bladder. The mucous membrane is, however, unaffected, and the specimen is referred to as the earliest indication of growth in this region. In the R.C.S. Museum is an enormous myxo-sarcoma, which has originated beneath the peritoneum in the neighbourhood of the urachus. It is, perhaps, eight times as large as the bladder, and yet the mucous membrame is entirely free.

In London Hospital Museum, 1918, the bladder of a female child is shown with a mass of sarcoma the size of an orange springing in front of the urethra, surrounding its neck anteriorly: the uterus and vagina are healthy. The bladder wall is healthy, the capacity normal.

(E) *Carcinoma of the Bladder propagated from the Abdominal Wall.*

Jude Hüe † mentions a case in which no urinary disturbance existed, and yet autopsy revealed the abdominal wall to be affected with colloid cancer, and the walls of the

* O'Connor, 'Trans. Path.,' vol. xiii (1862), p. 90.

† Jude Hüe, quoted by Féré, 'Cancer de la vessie,' p. 22.

bladder to be extremely thick, and three quarters of its cavity to be occupied by two friable gelatinous masses which sprang from a large base of origin at its upper and anterior part.*

(F) *Growth of the Pelvic Walls attacking the Bladder.*

Landeta † records a case of *enchondroma of the bladder propagated from the pelvis.* Female, æt. 32, began to have a feeling of weight in the perinæum and thighs four months before death. The growth rapidly became visible to sight and touch. The bladder, however, performed its functions perfectly. Autopsy showed the bladder to be of great capacity. Its walls were hypertrophied. In the thickness of the muscle were roots and fibres of cartilage, more pronounced towards the base, and a mass was found around the neck two inches thick. The mucous membrane was hypertrophied and degenerated.

Malignant Growth of Bladder springing from Pubes.

Kingdon ‡ has placed on record a case of *carcinoma of the pubes which involved bladder;* a mass of cancer about one and a half inches thick was found to have grown from the left brim of the pelvis, and to have invaded the left side of the bladder. The patient suffered from tibial cancer as well.

Malignant Growth of the Front of the Spinal Column may affect the Back of the Bladder by Contiguity.

There is a considerable element of doubt in the cases which are recorded to illustrate this method of invasion; for it sometimes happens that a softish growth of the posterior wall may implicate all the glands along the spinal column, and cause enormous tumours to be developed.

(G) *Malignant Disease of the Bladder propagated from the Penis.*

Usually the sarcomata or carcinomata which originate in the corpus spongiosum or corpora cavernosa, extend into the

* Albarran refers to this in 'Tumeurs de la vessie,' p. 453, No. 76.
† Landeta, 'Bull. Soc.,' 1861, p. 191.
‡ Kingdon, 'Path. Trans.,' vol. i, p. 524.

ischio-rectal fossa, and invade the rectum and the pre-vesical tissue in preference to the bladder, as occurred in the following case:—J. C—, æt. 52. Parents died of old age. No family cancer history. Three months before death he began to suffer from painful and frequent micturition and frequent desire to empty rectum; œdema of left leg appeared. A large mass quickly grew from the perinæum and extended into both ischio-rectal fossæ. He became greatly emaciated and died exhausted.

On post-mortem the malignant growth was found to have commenced in the corpus spongiosum, and to have reached the perinæum by way of the fossæ.

I have recorded another case which I had under my care at the London Hospital.*

Holmes Coote † has recorded the following case, but it is doubtful if the penis or the bladder was the site of the primary growth. The patient had had difficulty with micturition, necessitating catheterism, for eighteen months. On post-mortem the skin of the penis was soft, normal, and quite moveable, the corpora cavernosa were distended to their uttermost by the infiltration of a semi-fluid creamy deposit. The corpus spongiosum and glands were infiltrated similarly. Cancer juice was found in the venous sinuses. Around the bulb of the prostate the tissues were matted together by a similar deposit of cancerous growth. The mucous membrane of the bladder was dark-coloured, sloughy-looking, and fœtid. A large circular ulcer with ragged, elevated, and indurated edges occupied its surface at the lower and right side of the organ. Patches of fungous growth projected from it in various situations. It measured 2 inches by 1½ inches, and involved the right ureteral opening. Secondary growth was discovered in the tibia.

(H) *Malignant Disease of the Bladder extending from the Vagina.*

Primary cancer of vulva (Rondot's case) and vagina frequently affects the bladder.

The diagnosis is easy, the treatment palliative; cases are not infrequent, and of no surgical interest.

* 'Path. Trans.,' xliii, p. 103.

† Holmes Coote, London 'Med.-Chir. Trans.,' 1864, t. xvii, p. 1.

Sarcoma of the Bladder propagated from the Vaginal Septum in Children.

Primary sarcoma * of the child's vagina sometimes (27 per cent.) invades the base of the bladder, and shows in four out of seven instances a tendency both in its original site and in its extensions to become polypoid. This tendency has been recognised by German pathologists, who have applied the term "racemose sarcoma" (Traubensarcom) to this variety of new growth.

D'Arcy Power,† who has collected twenty-six cases of this disease, notices the following six cases of vesical implication from a vaginal source.

Soltmann ('Jahrbuch für Kinderheilk.,' Bd. xvi, p. 418), urinary bladder involved secondarily; a growth of the size of a walnut grew from the trigone.

Körner (Pick, 'Arch. für Gynäk.,' Bd. xlvi, 1894, p. 220), the vesico-vaginal septum was infiltrated; there were polypoid masses springing from the posterior bladder wall.

Thomas Smith ('American Journ. of Obstetrics,' vol. xvi, pl. 555), base of bladder occupied by a nodulated firm growth.

Demme (*v.* Pick, 'Arch. für Gynäk.,' vol. xlvi, p. 218), red and pale polypoid growths in urinary bladder.

Sänger. The posterior wall of bladder had a tumour the size of a walnut.

Weinlechner ('Wiener klin. Woch.,' 1889, p. 109), ulcerating sarcoma infiltrating base of bladder; it was papillomatous.

Perhaps the most fully reported and instructive case of sarcoma invading the child's bladder from the vagina is recorded by Howard Marsh.‡ Sir Henry Thompson quotes this case as a primary myxoma of the child's bladder. This is quite an error. The report of the Morbid Growths Committee states that the tumorous formation was merely an overgrowth of connective tissue. This view also I hold to be quite untenable, and that clinically the growth appeared at the orifice of the vagina before any symptoms of bladder trouble were noticed; and the entire history of the case is quite

* D'Arcy Power believes that it originates in "the connective tissue of the pelvic organs, and extends into the bladder, urethra, uterus, or vagina." Whether it affects the vagina alone, or whether it infiltrates all the neighbouring organs, it shows an almost constant tendency to become polypoid or multiple.

† D'Arcy Power, 'St. Bartholomew's Hospital Reports,' 1896.

‡ Howard Marsh, 'Path. Trans.,' vol. xxv (1874), p. 178.

typical of sarcoma affecting the bladder from the vagina. Pathologically it will be found (*vide* Sarcoma of Children) that the sarcomata of the bladder in children rarely affect the contiguous organs, probably because the little one dies so quickly from backward pressure and suppurative renal changes.

The report of this case together with the description of the microscopical appearances so impressed me with its probable sarcomatous nature, that I wrote to Mr. Butlin, who first examined the growths after removal. He answered, "I thought the disease sarcomatous, and did not believe that the report of the Morbid Growths Committee was correct; but I am bound to confess that the sections I made were not a success on account of the brittle condition of the growths." (Mr. Butlin made the post-mortem in this case.)

The gross appearances of this bladder, as described by Mr. Beck, are so characteristic of the disorder that I give them in full.

"The specimen submitted to us for examination consists of the bladder, uterus, and vagina of a child aged two years, on the mucous membrane of which are large masses of soft polypoid growths. Those on the bladder are limited to the base and neck, while those on the vagina are almost confined to the anterior surface where it is in contact with the bladder. Between the bladder and vagina is a dense solid mass about one inch in thickness, corresponding to the surfaces from which the polypi are growing. On the left side this projects from between the bladder and vagina, forming two rounded masses on the surface of the specimen. Where the bladder has been cut open through the smaller polypoid growths, the wall is found to be greatly thickened. The inner surface is composed of the thickened mucous membrane from which the polypi sprung. The muscular coat is hypertrophied, and the bundles of fibres widely separated by tissue, having the appearance to the eye of fibrous tissue. The tumour is nowhere sharply defined." *

* Sarcoma of the child vagina may only affect the bladder by pressure. D'Arcy Power has recorded ('Brit. Med. Journ.,' Oct. 19th, 1895, p. 973) the case of a child $2\frac{1}{2}$ years old, who had died with symptoms of uræmia consequent upon pressure exerted on the urethra by vaginal polypi. The vagina was much dilated, and from its right wall a mass of new growth projected (round-celled sarcoma). The whole of the vaginal mucosa was beset with polypi, some of which were pedunculated and myxomatous, and others were composed of a round-celled sarcomatous structure like the main growth.

Primary Uterine Cancer affecting Bladder.

Lebert has only found the bladder healthy in one fifteenth of uterine cancer cases; Max Heilborn,* from the autopsies of 1734 females, found thirty-three cases of vesical cancer, and only four of these were *primary*. The rest were of uterine origin. Féré, in fourteen cases of uterine cancer, found the bladder attacked ten times.

In Hasenclever's record † of the Pathological Institute at Berlin from 1868 to January 1st, 1880, thirty-two cases of cancer in the female bladder are found. Of these, only one was primary.

Gurlt ‡ found the female bladder affected in twenty cases out of 3449 cases of uterine cancer.

I have excerpted sixteen cases of uterine cancer propagated to the bladder which occur in the post-mortem record of the London Hospital. They are scattered over fifty-eight years. They need not be quoted. The curious character in the change of the mucous membrane of the bladder as the malignant growth invades it is remarked upon on p. 34.

2. *Secondary or Metastatic Growth in Bladder.*§

Cases are recorded in the literature in which the bladder has been found to contain metastatic deposits; but such cases are of the rarest, and the bladder in this respect seems to enjoy the same immunity as the prostate. ‖

I have only met with one case,¶ and even this is open to criticism.

Case 1.—H—, æt. 61, seven months before death noticed a little blood in urine, which increased, and at first proved to be under control of hæmostatics; latterly cystitis with frequency of micturition and pain was suffered from.

* Heilborn, 'Krebs der Harnblase,' Berlin, 1868.

† Hasenclever, 'Zur Statistik der Carc. des Harnblase,' Berlin.

‡ Gurlt, 'Langenbeck's Archiv,' Bd. xxv, Heft 2.

§ In connection with secondary implication of the lower urinary tract I may, perhaps, seize the opportunity to point out how rarely (2 per cent.) the bladder is secondarily affected by deposits of tubercle originating in the lungs. Thus in 1000 consecutive cases of chronic phthisis only six cases of vesical tuberculosis were noted. Four cases of prostatic deposit, and ten cases in which the prostate, bladder, and vesiculæ seminales were involved, are also recorded. The statistics were kindly taken out for me by Dr. Soltau Fenwick from the Brompton Hospital records.

‖ Five cases out of 100 prostatic carcinomata which I have collected fall into the grouping of metastatic carcinoma. The cases recorded by Longstaff, Mercier, and Guyon were all secondary to carcinoma of the stomach, Gibbons' case to the dura mater, and my own—the fifth case—found its primary site in the lung.

¶ 'Trans. Path. Soc.,' vol. xxxix (1888), p. 169.

Autopsy.—On opening the bladder 2 ounces of puriform urine mixed with shreds of necrotic tissue and phosphatic *débris* were evacuated. The walls of the bladder were thick, but not markedly hypertrophied. The cavity was contracted to the capacity of 4 ounces. The mucous membrane showed signs of a severe form of chronic cystitis. Its surface was sprinkled here and there, especially posteriorly, with a number of millet-seed sized patches of yellowish-white deposit, distinctly carcinomatous in character. The colour of these growths marked them off very abruptly from the dull red mucous membrane around. Springing from the upper lip of the right ureteral orifice was a cherry-sized, slender-pedicled, oval-shaped tumour, which on section proved to be firm and white, but did not exhibit any appearance of carcinoma.

The prostate was absolutely healthy, and small for the age of the patient. The right kidney was half its natural size, and a section of it showed that very little renal structure remained. It had been converted obviously by backward pressure into a loculated sac possessing a half-inch-thick wall of renal substance. The right ureter and pelvis were correspondingly dilated. The left kidney and ureter were healthy, the former much hypertrophied compensatorily.

A large deposit of cancer existed in the left lobe of the liver and in the adjacent part of the stomach. The right lobe of the liver contained innumerable similar deposits of greater and lesser sizes. The lungs were œdematous; the heart was thin, and its muscle friable. The microscope showed the mass in the liver to be carcinomatous. The deposits in the mucous membrane of the bladder were of a like nature, and were apparently, from their multiplicity and minuteness, a *secondary* deposit.

The small tumour, pedicled at the right ureteral orifice, proved to be composed of fibrous tissue, containing here and there spots of carcinomatous material.

From a careful consideration of the facts revealed by the autopsy, it would seem (1) that the small fibroma had been a latent occupant of the bladder for a lengthy period, and had exerted a fair amount of obstruction upon the right ureter, for on no other grounds could the extreme condition of chronic interstitial nephritis of the right kidney be explained; (2) that the symptoms of the carcinoma of the stomach were trifling, and masked by the vesical hæmorrhage; (3)

that the cystitis may have been a predisposing cause for the deposition of the carcinoma, for the deposit was evidently quite recent.

Case 2.—Guy's Hospital Museum, 2104[20], is a bladder containing a small melanotic growth which was secondary to sarcoma of the left eye of a male aged 32. It had existed two and a half years, and had produced multiple cuticular deposits one year before death. Mr. Targett, who has recently examined this specimen, describes it as follows ('Path. Trans.,' vol. xlii, p. 214, 1892):

"A soft pigmented filbert-sized polypus is attached by a slender pedicle to the mucous membrane of the posterior wall, one inch from the orifice of the left ureter. Its smooth surface is stippled with patches of brown pigmentation. The pedicle is composed of mucous membrane about one third of an inch in length. Histologically the tumour is composed of small round and oval sarcomatous cells, with granules of pigment scattered among them."

Case 3.—Guy's Hospital, 2104[10]. Susan G—, æt. 56, under Dr. Gull's care in 1855 for scirrhous cancer of the right breast, and abundant secondary deposits in the lungs, pleura, pericardium, mediastinal and lumbar glands. Mr. Targett has recently examined this, and describes it as follows ('Path. Trans.,' vol. xli, p. 180):—"At the fundus of the bladder, and extending down its posterior wall, is a hard mass of growth, which is situated entirely in the muscular coat. It forms a lenticular swelling about two inches in diameter, and half an inch at its thickest part. The mucous membrane is unaffected, being separated from the tumour by a thin stratum of muscular fibres, and the peritoneal coat though adherent to the growth is not invaded by it. The remainder of the bladder is quite healthy. Microscopically the growth is a scirrhous carcinoma, consisting of small alveoli embedded in much fibrous tissue. It is found between and within the bundles of muscular fibres, and is more abundant in the deeper parts of the muscular coat away from the mucous surface."

Case 4.—Henocque.* Cancer of ovary with secondary deposits in the pleura, lung, peritoneum, and mucous membrane of bladder.

* Henocque, 'Bull. Soc. Anat.,' 1856, p. 25.

Case 5.—Rosapelly.* Female æt. 74, who had suffered from right hemiplegia and aphasia for six months. On autopsy a number of large primary tumours of a gliomatous nature were found in the brain, and the entire bladder was covered with a number of small rounded tumours, raising up the mucous membrane, and varying in size between a lentil and a nut.

Case 6.—Angelot † records the case of a male æt. 71 who had had a melanotic tumour removed by caustic from the right groin, and in a few months the bladder was found on post-mortem to be strewn with small secondary melanotic growths.

Case 7.—Clutton.‡ Male æt. 62. Eleven months before death a fixed tumour on the left parietal bone was noticed. It had a soft fluctuating centre, and an infiltrated indurated margin.

This tumour perforated the skull and affected the subjacent brain and dura mater. No secondary deposit was found in any viscera except in the bladder, which is described as follows :—" The left side of this organ is occupied both on its inner and outer surfaces by a tumour of about the size of an orange. It is irregularly nodular, and projects into the interior just above the orifice of the left ureter. It stands out abruptly, and is not in any way diffused along the walls. On its outer surface it is equally circumscribed, and appears to have involved the left vas deferens. It is chiefly composed of round or oval sarcomatous cells, the skull tumour being an alveolar sarcoma."

Case 8.—Case by Hillemand, recorded by Albarran (op. cit., p. 415), in which many small secondary melanotic masses in the mucous membrane of the bladder were discovered in a case of general melanosis.

Case 9.—A case observed by Bouisson and Halle (Albarran) in a case of melanosis of the optic bulb ; the secondary deposit in the bladder was the size of a pin's head.

These nine cases are the only ones I can find recorded in 1000 cases—*i. e.* about 1 per cent.

* Rosapelly, 'Bull. Soc. Anat.,' 1872, p. 159.
† Angelot, 'Bull. Soc. Anat.,' 1872, p. 411.
‡ Clutton, 'Path. Trans.,' vol. xxxiv (1883), p. 212.

I mention them only as important from a pathological aspect. It is interesting to note, however, that in six out of nine the growth was of sarcomatous nature, and that four of these originated in the head (the eye, brain, skull).

Note upon the Changes which take place in the Mucous Membrane of the Bladder upon the approach of Invading Malignant Growth.

When a carcinomatous growth invades the bladder wall from some source outside that viscus the mucous membrane

Fig. 15.—A pure villous papilloma surrounded by carcinomatous masses. Pointers mark the ureters and urethra.

which is being implicated generally assumes a tuberous appearance, or grows out in the form of cauliflower ex-

crescences according to the rapidity and character of the invasion. These masses resemble the infiltrating primary carcinomatous growths of the bladder in their aspect.

In some cases, however, it is different. The subjacent growth appears to be heralded by the formation of densely set short villous processes * which carpet the area affected. Whether this villous condition is transient or permanent I am unable to say. It may be that the papillomatous surface falls off by ulceration, and those specimens which are encountered in museums, showing the villous condition, have been secured in the earlier periods of the disease, and merely mark the penultimate stage of complete invasion.

It is certain that a primary carcinomatous growth of the bladder is able to evoke in the surrounding mucous membrane the formation of what may be termed "pure" villous papillomatous growth, for I have shown that such benign growths co-exist with the carcinoma in 55·5 per cent. of the specimens of malignant disease of the bladder.

As an example, Fig. 15 represents a bladder which I removed from a male patient aged fifty-eight.

"Above the right ureteral orifice is a benign villous papilloma, with some chronic inflammatory change, but no evidence of malignant disease. Around it is a dense villous epithelioma (squamous-celled), not the variety which one would expect to be due to malignant transformation of a papilloma" (Targett).

It is logical, then, to assume that a carcinoma approaching from without may possess the same irritative (?) power as growth affecting the surface directly by contact.

I encountered by chance another very good instance of this form of invasion, and was able to demonstrate it in a very early stage. A patient aged sixty applied to me for occasional attacks of retention, which were relieved by catheter. Between the attacks he had great difficulty, pain, and hæmorrhage in urination. These symptoms were of one month's duration. I found the prostate typically carcinomatous. It was enlarged, irregular, and nodular. It was intensely hard in parts. I determined to put a permanent catheter in supra-pubically, and before doing so I examined the bladder by means of my supra-pubic electric cystoscope (compare section on Diagnosis). Sprouting from the anterior wall of the bladder immediately above the urethral orifice was

* The experienced pathologist will not fall into the error of mistaking macerated growth or tags of ulcerated mucous membrane for villous covering.

a cauliflower tuft of villous growth the size of a walnut. This was evidently the outrunner of the extension along the anterior wall from the carcinoma of the prostate.

The Middlesex Hospital Museum contains a very striking and beautiful example of the change of aspect which a growth originating in one mucous membrane may assume on invading another. No. 1745 is the section of a male bladder and rectum. There is a fistulous opening on the base of the bladder leading into the rectum. The communication is obviously due to malignant growth. Surrounding the bladder orifice of the fistula is an extensive villous growth, the branched processes of which exceed in length any I have seen, except one preserved in Norwich Museum. Each villus is nodose, and measures more than one inch and a half long. The general aspect of the bunch of villi is that of a loaded Russian knout. On turning the specimen round, the rectal surface will be seen to be extensively ulcerated, and the edges of the fistula "rolled" like an epithelioma—for the most part smooth.

Dr. Voelcker observed a similar condition in a specimen of uterine cancer. He says,* "I should like to call attention to a point I have noticed in a case of carcinoma of the cervix uteri which was invading the bladder. In this case projecting into the bladder was a villous growth which had all the microscopical appearances of a simple villous tumour, while the uterine growth was a malignant adenoma."

Still further, when an invading growth has implicated and projected from the surface of the bladder it apparently possesses in some instances the power of producing villous papillomata on the apposed surface by "contact."

Thus in St. Mary's Hospital (before reconstruction, 1891) there was a specimen of soft carcinoma of the left lobe of the prostate which had implicated the adjoining left lateral wall. On the right lateral wall, exactly opposite the ulcerated malignant surface on the left lateral wall and base, were two isolated walnut-sized patches of pure villous growth. They were soft and sessile.

Invading carcinomata, then, may evoke "villous" change in the mucous membrane. This is pathologically interesting and clinically important. Pathologically it raises the question as to whether a certain form of growth has the power of causing the efflorescence of villous growth, for it is not found in all cases, or as to whether the individual thus affected had a predisposition to the formation of villous papilloma in the

* 'Path. Trans.,' vol. xlvi (1895), p. 133.

same way that some patients show a tendency to produce cutaneous warts. Clinically it is of extreme importance to the operator, who should be aware of the fact that all villous surfaces seen by the cystoscope or found in the urine are not always evidences of benign growth, nor are always due to *primary* malignant vesical growth.

It has been already noticed that sarcomatous growth in children, affecting the prostate (p. 8) or vagina (p. 25), frequently give rise to polypoid excrescences on reaching the bladder. In adults, on the contrary, sarcomatous invasion does not, as a rule, induce polypoid growth.

CHAPTER II.

NON-MALIGNANT CYSTIC TUMOURS IN THE NEIGHBOURHOOD OF THE BLADDER.

Certain non-malignant tumours, such as hydatid cysts, are situated in the outer wall of the bladder base; and though they cannot be included in the section of invading growths of the bladder, yet they demand consideration. Not only do they exert direct pressure upon the bladder, and evoke vesical symptoms, but they sometimes burst into the bladder, and by their bulk and position may mislead the clinician into a false impression as to their origin and their nature.

The same remarks apply to other cystic formations in the neighbourhood of the posterior wall of the bladder, as dermoid cysts of the ovary.

Hydatid Cysts of the Bladder Wall.

Although hydatids of the liver, omentum, and thorax occur not infrequently in hospital * and in private practice,† the pelvic viscera are very rarely affected. Even in countries, as Australia, where the disease is rife ‡ such cases are but seldom encountered. In the literature of 200 years I have been able to find only 100 cases recorded, and of these a little less than half relate to women.§ The tense sacs which this parasite forms near the neck of the bladder need some notice, for they simulate growth affecting the bladder by their position and clinical aspects.

* Not more than one in 10,000 in-patients treated in London hospitals suffers from hydatid disease.—Dr. J. Davies Thomas, 'Transactions of Intercolonial Congress, Australia,' 1889, p. 330.

† Deaths from hydatid disease in England and Wales from 1871 to 1876 were one in 10,893 deaths from all causes.—*Ibid.*

‡ One in 175 of all cases admitted into the Victoria Hospital suffers from hydatid disease.—*Ibid.*

§ This follows the rule, for 50·86 per cent. of every form of hydatid disease are males, and 49·14 per cent. are females.

Hydatid cysts which have been found in the male pelvis have generally * been proved, on careful dissection, to be situated in the posterior wall of the bladder, in the cellular tissue which intervenes between its muscular layer and the peritoneum (Charcot,† Davaine,‡ Targett), or in the angle between the same layer and the recto-vesical sheath and the posterior wall of the prostate. I believe that in the greater number of cases the parasite first locates itself in the latter situation, and as it enlarges it extends in definite directions.

Apparently the muscular and fascial diaphragm of the pelvis check the downward enlargement of the cyst, so that it spreads sideways and backward, pressing up the recto-vesical pouch of the peritoneum. Its tendency is, however, chiefly upward along the line of least resistance—the axis of the true pelvic cavity. As the enlarging cyst displaces the small intestine and obliterates the pouch of Douglas it gradually strips off the peritoneum from the back of the bladder, and forces that viscus upward and against the posterior surface and brim of the pubes, whilst it crowds the rectum into the sacral curve (Fig. 16, A).

As time goes on, the cyst gradually emerges from the true pelvis, and is now for the first time observed by the patient or his practitioner, and the obscure symptoms, dependent on rectal or vesical obstruction, from which he has probably been suffering, are at the same time explained.

It is only now that the cystic tumour can be mistaken for growth, for as the hydatid sac increases its nature becomes apparent.

Separating the peritoneum from the back of the bladder, or carrying that viscus bodily up with it (Fig. 16, B), the cyst at length occupies the pre-peritoneal space almost as high as the umbilicus, and in extreme cases still higher. The projection of the cyst forward is often so accen-

* In one of Bright's cases (Case 2, p. 22, 'Abdominal Tumours') "cysts are appended to the bladder." The mesorectum was occupied by a cyst in three cases. Two were male cases (Beauvais, Wunderlich) and one a female case (Obre). In two cases a small cyst was found situated towards the apex of the bladder (Richter, Budd). In one case (Le Louis) the cyst is described as being pedicled to the back of the bladder.

† Charcot rebuts Hunter's statement that the pelvic cysts escaped from a ruptured cyst in the liver or kidney, and gravitated into the pelvis. Charcot adds, "*C'est dans le tissu cellulaire sous-péritonéal* du petit bassin que, suivant nous, les kystes hydatiques de la région pelvienne prennent le plus souvent naissance. Chez l'homme, *ils n'ont pas d'autre siège primitif;* le plus généralement alors, c'est entre le rectum et le col de la vessie qu'ils se développent en les refoulant chacun de leur côté; ils peuvent cependant encore se développer entre le péritoine et la face postéro-supérieure de la vessie."—Charcot, 'Mémoire,' loc. cit.

‡ Davaine, 'Traité des Entozoaires,' 2nd edit., Paris, 1877.

tuated by the over-distended bladder, that the belly assumes the appearance of containing a large abdominal tumour.*

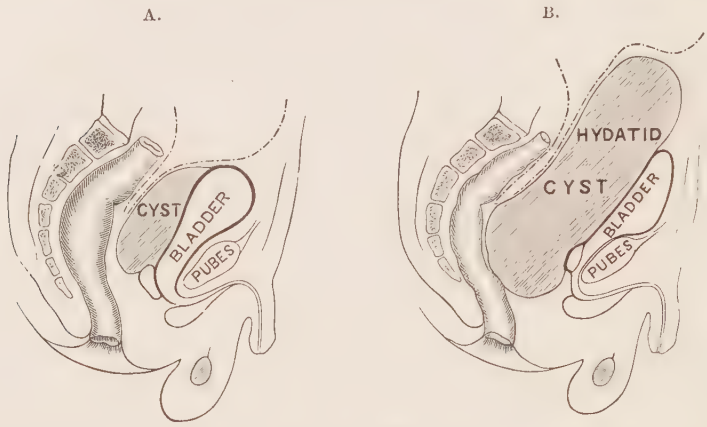

Fig. 16.

The main stress of the pressure of the enlarging cyst falls upon the bladder and ureters. The former is at first usually carried vertically upward and doubled over the brim of the pubes. So powerfully is the bladder nipped against the bone that it is often transformed into an hour-glass shape, the upper compartment often containing many ounces of urine; thus in James's case the amount found in the upper portion of the bladder was two pints.

In the larger cysts the dislocation is carried still further, and the bladder is lifted out of the true pelvis and dislocated into the left † iliac fossa (Bryant). In one case it was even forced into a left scrotal hernia (Perrin). The drag upon the membrano-prostatic urethra lengthens that tube to a remarkable extent, causing catheterism to be extremely difficult or impossible.

But the organs which are affected most severely and most dangerously are the kidneys. Not only are the ureters acutely strangulated against the sharp brim of the true pelvis by the cyst after it has fully engaged the inlet, but the intra-pelvic portions of these conduits suffer considerably. Attached as they become to the lower part of the outer walls of the

* One man, æt. 59, who was thus affected, was described "as if far advanced in pregnancy." Women are recorded as having been treated for ascites, ovarian tumour, pregnancy, &c.

† In two cases the dislocation was towards the right side. I am sure that the method in which the dislocation of the bladder is effected depends to a great extent as to whether the cyst can easily separate the peritoneum from the back of the bladder, or whether it merely forces the recto-vesical fold of peritoneum and the attached bladder directly upward.

cyst, they are dragged outward from their insertion into the bladder as the cyst spreads laterally. Their inclusion in the fibrous wall of the cyst, moreover, cripples their muscular action, and they finally become merely over-stretched, flaccid, and dilated tubes, liable at any minute to become affected by such inflammatory processes as may originate in the contents of the cysts. Moreover, any ascending inflammatory trouble from the bladder places the kidneys in extreme danger, for they have become converted more or less by this time into thin-walled sacs consequent upon the urethral obstruction.

Three cases which have been under my care are good illustrations of the various grades in the severity of the disease.

Case 1.—In 1886 I saw, with my friend Mr. Buncombe, of Mile End, a patient æt. 50. He was complaining of intense abdominal pain, of some constipation, but no dysuria. On examination I found an elastic fœtal-head sized abdominal tumour, which obviously sprang from the pelvis, and which extended up to the umbilicus. Although it exerted some pressure on the pelvic viscera, both bladder and rectum were

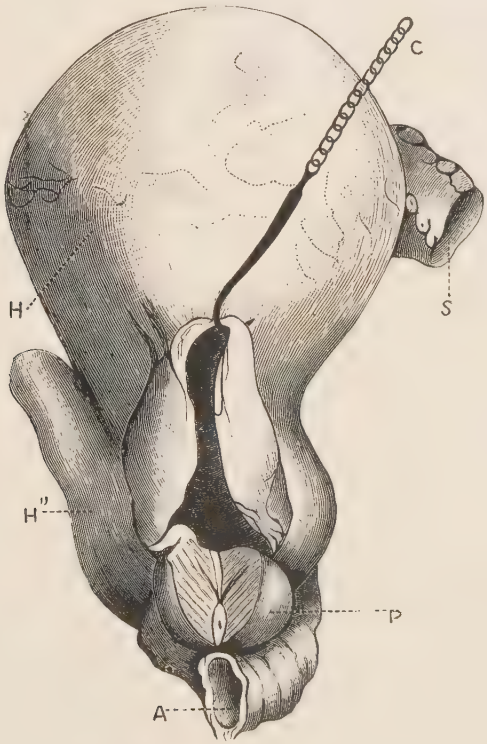

Fig. 17.

able to discharge their contents. He asserted that six months previously he noticed a tumour in his belly which rapidly increased in size and caused him great pain. An operation was refused, and he died a week after I saw him. An autopsy disclosed a large bilocular hydatid cyst, which had obliterated the recto-vesical pouch and had wedged the rectum and bladder apart. The upper cyst was much the larger (Fig. 17, H,

R.C.S. Museum, 3747B), and was evidently a daughter-cyst which had herniated from the pear-shaped lower mother-cyst, H″. Both contained many scolices. Their walls were extremely thick and laminated, and were calcareous in parts. This case is recorded in the 'Pathological Transactions,' vol. xxxvii, p. 317.

Case 2.—In September, 1890, I was asked by Mr. Robert Debenham to see a patient who was suffering from suppression of urine. I found a young fellow of 20 in a grave condition of exhaustion. He was much emaciated, and stated that he had not passed water for two days and a half. His history, which was given in a whisper and with difficulty, was as follows:—For some years he had suffered from frequency of micturition in the daytime, and had to rise twice at night to empty his bladder. He had never seen any blood in the urine, which had always appeared healthy. He had complained for nine months of headache and morning sickness; the latter symptom had continued up to the date of the present attack, but the headache had ceased two months ago. These symptoms suggested that an insidious interstitial nephritis had been progressing for some months. There was no supra-pubic distension. On the right of the pubes a firm fleshy mass could be felt. This I took to be an empty hypertrophied bladder pushed out of the pelvis. On passing the catheter there was a hitch at the prostate, but it entered easily and no urine was evacuated, the instrument being withdrawn without even a drop in the eye. To ascertain whether any pelvic obstruction was causing the suppression, I examined the rectum. The finger encountered a large, elastic, semi-fluctuant mass which did not spring from the prostate, but was obviously in the space between the rectum and the bladder. Many small shotty glands could be felt in the peri-rectal tissues. I did not know whether I was dealing with a soft sarcoma or a hydatid. I determined to aspirate *per rectum*, which I did next day. After proving by means of the catheter that the bladder was still empty, I withdrew by aspiration through the rectal wall three or four ounces of clear hydatid fluid from the recto-vesical cyst, and at once two ounces of blood-stained urine flowed into the bladder and were evacuated by the catheter. Obviously by reducing the bulk of the pelvic hydatid I had removed the pressure on the dilated ureters, and had thus enabled them to empty their dammed-up contents into the bladder. Next day the patient passed thirty ounces of urine voluntarily, and I proposed to incise supra-pubically, to lift up the peritoneum and open and drain the cyst. On the morning fixed for the operation (the sixth day of the attack) the urine again stopped, and at 8 a.m., whilst he was being supported on the night stool, he dropped back dead.

Autopsy.—The kidneys were large, thin-walled sacs containing a quantity of urine. Each ureter was dilated to the size of a child's small intestine, and both these conducting tubes were full of urine. As the ureters turned over the pelvic brim they were compressed by a fœtal-head sized, milk-white hydatid cyst, which filled and projected a little way from the brim of the true pelvis. The bladder was dislocated upward and to the right. Its upper half contained a couple of ounces of urine, for it was rather compressed into an hour-glass shape against the edge of the pubes, the lower and empty compartment being flattened against the posterior surface of the pubes (R.C.S. Museum, 3747C).

This case illustrates first the insidious but disastrous effects of the pressure upon the ureters; second, the danger of delay in relieving the backward renal pressure; third, that on the slightest reduction in the tenseness of the cyst the ureters and bladder empty themselves, and the kidneys return to work.

The case is more fully described in the 'Pathological Transactions,' vol. xlii, p. 201.

Case 3.—A thin but healthy-looking man, æt. 30, was sent to me by Dr. Buck, of Hampstead, for an abdominal tumour. He gave the following history:—Up to seven years ago he was in perfect health. At that time he began to suffer from constipation, malaise, short breath, and other vague symptoms, which were referred to indigestion. There was at first no trouble with the urine. Quite recently he had noticed some obstruction to micturition, and lately had so much difficulty in emptying his bladder that he has been forced to press upon his belly to aid the expulsion of urine. Contrary also to his usual habit, he has had to pass water every three hours, day and night. Three or four weeks ago he felt, when he lay upon his back, a lump, situated above and to the right of the pubes; but it disappeared when he stood up. This small tumour has grown very rapidly in size, so much so that when he came to see me it was quite visible in the supra-pubic region. He had lost much flesh recently.

After he had passed healthy urine I found a well-defined elastic tumour, the size of a large cocoa-nut. It was placed above the pubes, and projected as high as the umbilicus. It was precisely like a distended bladder, but firmer and less elastic. The rectum was found to be blocked by the lower end of the tumour, and the pelvis appeared filled with it. The prostate was found to be small in size. On tapping the supra-pubic tumour with the fingers a fremitus or thrill was communicated to the forefinger in the rectum. It was obvious that I was dealing with a cyst, and as there was no evidence of a sacculated bladder, and as the thrill was typical, I diagnosed a hydatid in the posterior wall of the bladder. On examining the urine to ascertain how far the ureters and kidneys had suffered from backward pressure, I found the secretion was quite clear but very pale. Its specific gravity was 1010, no albumen was present, and the percentage of urea was 1·2. This evidence of backward pressure decided me to operate at once. On making a median supra-pubic incision, I came upon a thick muscular body which covered the front of the cyst, and which I at once recognised as the empty hypertrophied bladder, thrust bodily upward from the pelvis. Mr. Bond, of Leicester, had encountered a similar difficulty in reaching a hydatid cyst of the bladder, and had been forced to extend the incision upward and open the peritoneum. I argued, however, that in the present case the cyst had grown rapidly, and that the portion above the pelvis would not have any very intimate attachment to the wall of the bladder. This proved correct, for I was able to dissect off the bladder from the cyst and to push the former to the left. As the bladder was dislocated more and more in this direction the milk-white wall of the pre-peritoneal cyst bulged forward. An aspirating needle was pushed in and its contents slowly withdrawn. A practical proof of the ureters having been pressed upon by the cyst was now obtained. As the hydatid cyst was evacuated we saw the bladder gradually distend with urine. Thirty-six ounces of clear hydatid fluid having been withdrawn, the cyst was pulled forward and a free incision was made into it. Ten ounces of brood capsules and scolices were then scooped out by means of a large kitchen spoon which I had handy. Finger exploration of the emptied cyst showed that it extended in every direction in the pelvis. An attempt was made to peel off the germinal layer of the cyst, but it was too thin, and therefore a double drain-tube was passed to the bottom of the sac, and the opening stitched to the skin incision.

The patient made an uneventful recovery. Before the operation his urine was 1010, and the urea 1·2 %; a year after the operation the urine had an average specific gravity of 1015, and at the end of the second year the specific gravity was 1020 and the urea 2 %, so that the renal backward pressure had, therefore, been recovered from. We know too little concerning the recuperative power of kidneys which have suffered from backward pressure, but I should believe that where the urine has remained sterile and the pressure has been of short duration the prognosis is favorable. There is no reason to doubt the ultimate recovery of the ureters from their atony, for I have shown how readily the bladder muscle of a young man recuperates after tight urethral stricture,* and the ureters are analogous in structure to the bladder. I do not apprehend any real danger from the bending or twisting of the ureters when the cyst has completely contracted, although this happens sometimes after draining broad-ligament cysts.

Literature.

I have found 100 cases of this disease in the literature of the last 200 years, the first being recorded by Dr. Tyson in 1687. It is sufficiently obvious that hydatid cysts in the pelvis are not common; Davaine places them in the lists as occurring in 7·9 % of all cases. A consideration of these recorded cases permits of the following conclusions:

Size of the Hydatid Cyst.—The size and shape of the hydatid cyst in the pelvis varies considerably; dependent, it would seem, upon the amount of its fluid contents. The similes used to give an idea of the size are "the sac was the size of an ostrich egg," "of a neckless quart bottle," "of a twelve-pound shot," "of a child's head," "of a fœtal head," "of a fist." They are recorded also as containing three pints,

* 'Cardinal Symptoms of Urinary Diseases,' p. 157.

eighty ounces, twenty litres, three quarts. Naturally the appearance of the belly in these cases has been sufficiently remarkable to attract attention and merit description. One man, æt. 59, is mentioned as if "far advanced in pregnancy," another as if appearing "three months pregnant." Such expressions as "treated for ascites," "simulating ascites or ovarian disease," "distended to two inches above the navel," are met with, and give the reader some idea of the appearance of those cases in which the cyst has caused the urinary bladder to become enormously dilated by pressure upon the prostatic urethra.

Structure of the Sac.—This varies greatly in thickness, "from a dense fibroid calcareous wall," a quarter of an inch thick, to "a clear transparent gelatinous sac, through which colonies of scolices could be seen growing on the inner surface" (Allen's case). Usually the sac is single, but in a few cases it was bilocular or even multilocular.

Position and Origin of the Sac.—This, as ascertained by careful post-mortem examination, is proved most often to be between the rectum and the bladder, and a fair number of dissections show that the sac originated, as Charcot first insisted, *outside the peritoneum*, between the muscular coat of the bladder and the recto-vesical sheath, the pouch of Douglas being practically free. Mr. Targett has also arrived at this conclusion. Doubtless mistakes have arisen by the pathologist finding the pouch of Douglas obliterated by localised inflammation from the irritation of the parasite, which had caused the peritoneal wall of the cyst to adhere to the front of the rectum and the surrounding parts. He had thus been led to believe that the sac had dropped from above into the true pelvis and grown there. This supposition has received colour from the fact that in a very large proportion of the cases other cysts are discovered coincidently in the omentum, the liver, the mesentery, the spleen, or the iliac fossæ.

Although the extra-peritoneal site is the general rule, yet certain very remarkable exceptions are mentioned:

(*a*) A hydatid cyst, the size of a man's head, was found after death to be filling the pelvis of a woman æt. 30; it lay between the uterus and the rectum, and had originated in the ovary, which had fallen into the pelvis and contracted adhesions there (Barret's, also Potocki's case).

(*b*) "A cyst, the size of a twelve-pound shot, was found free and moveable between the viscera; its pedicle, the size of a little finger, was fixed to the posterior inferior ligament of the bladder" (Le Louis).

(*c*) Female æt. 55, "senile uterus pushed forwards and to the left by a tumour the size of a child's head; this was adherent to the posterior wall of the uterus by repeated attacks of circumscribed peritonitis near the tumour. A band was discovered a foot long running from the tumour to the right lobe of the liver; the connecting link was as thin as a thread. The deep yellow colour of the membrane points at the liver as being the original site of the cyst. It had developed in the substance of the liver, become protruded from its surface, then pediculated, and hanging down into the pelvis acquired adhesions there" (Freund and Chadwick).

(*d*) In four instances especial mention is made that the hydatid formed in the prostate gland.

Sir Henry Thompson, after quoting from the literature six cases of hydatids between the bladder and rectum ('Diseases of the Prostate,' 5th edition), says, "It is doubtful if hydatids are ever met with in the prostate." These cases, therefore, deserve mention.

1. Lowdell ('Med.-Chir. Trans.,' vol. xxix, p. 253). "Male æt. 64. In the situation of the prostate gland was a tumour larger than a fœtal head, which, when cut open, proved to be a hydatid cyst so full of hydatids compressed together that the cut surface presented a wavy appearance, the true substance of the prostate being lost in this thickened cyst. The course of the urethra was healthy throughout, but the prostatic portion had been so pressed upon by the tumour that in attempting to pass the catheter numerous false passages had been made in every direction. With the exception of a small portion in front of the false passage through which the catheter was passed, the whole of the substance of the prostate was lost, but whether the hydatid cyst was formed in the prostate itself, or whether the cyst originated externally to the gland, is a matter of doubt."

2. Tillaux ('Bull. Soc. de Chir.,' tome ix, 1883, p. 143, "Kyste hydatique de la prostate"). Male æt. 43. A year before admission the patient had a difficulty in responding to the call of the bladder at night. There was coincident constipation. A hydatid cyst, which M. Tillaux had no doubt sprang from the substance of the prostate gland, was found on rectal examination and opened. It had been mistaken for a cold abscess, for the patient had scrofulous scars on the right side of the thorax. Cured.

3. Millet ('Bull. Soc. de Chir.,' vol. x, 1884, p. 551). Male æt. 59. Retention of urine; a large tumour was found occupying prostatic region, and which also filled pelvis. In the attempt to pass a silver catheter the point was plunged through the wall of the hydatid cyst, and 700 grammes were evacuated. This case ultimately got well, and the author believes it was situated in the prostate.

4. Butreuille ('Bull. de la Soc. Anat.,' 1878, p. 265). Male æt. 69. Retention of urine for many days, difficulty in catheterism, false passage "sonde à demeure." An enormous tumour was found in the position of the prostate, but was supposed to be an abscess, surgical kidney, death. *Post-mortem.*—A multilocular transparent cyst occupied the anterior portion of the prostate, separated only from the urethra by a thin bridge of prostatic tissue. At the base of the left lung was a nut-sized hydatid cyst.

The last case appears to be quite genuine, but as a comment upon Tillaux's and Millet's cases, and, in fact, upon any such not verified by autopsy, I would refer to Walther's case ('Prog. Med. Paris,' 1887, 2nd ser., vi, 78). A vertical section of the pelvis was made in the antero-posterior direction, and a hydatid cyst, the size of a small apple, was found placed 1 cm. below the base of the prostate, its upper margin being in contact with the recto-vesical *cul-de-sac*, to which it was strongly adherent. It is evident how easily a subprostatic hydatid (and many extend beneath the prostate) may be diagnosed as being purely prostatic.

In 52 cases in which the post-mortem has plainly indicated the exact site of the hydatid cyst, the following positions were noted:

	Cases.
Between the posterior wall of the bladder and rectum	22
Between the neck of the bladder and rectum	4
Prostatic (?)	4
Pedicled to the posterior wall of the bladder	1
"In the cellular tissue of the right seminal vesicle"	1
To the right of the bladder	1
Cyst on either side of the bladder	2
To the apex of the bladder	2
Vesical orifice of each ureter	1
Between the bladder and the uterus	5
Between the uterus and the rectum	3
Between the vagina and the rectum	2
To the uterus and surroundings	1
In the mesorectum	3
Total	52

Mallez, 1878, quoted by Nicaise, gives "hydatid tumour of the prostate, puncture, suppuration, cured" ('Soc. de Chirurgie,' vol. x, p. 554, 1884, case 26). I have not been able to get the original history of this case.

Literature.

Tyson, 'Phil. Trans.,' 1687, No. 188, p. 332.
Sibille, Chopart, 'Maladies des Voies urinaires,' 1821, t. ii, p. 146 (case read in 1775).
Gery-Cullum, 'Med. Observ. and Inquiries,' 1812, vol. vi, p. 91 (case read in 1778).
Le Louis, Acad. de Chirurg., Nov., 1789.
Hunter, 'Med.-Chir. Trans.,' 1793, vol. i, p. 35.
Richter, 'Journ. de Chirurg.,' Nov., 1789.
Le Sauvage, 'Bull. de la Fac. de Méd.,' 1812–13.
Colson, 'Rev. Méd. franç. et étrang.,' Paris, 1827, vol. iv, pp. 34—40.

Brun, 'Thèse de Paris,' 1834 (quoted by Legrand).
Seerig, 'Schmidt's Jahrb.,' 1834, p. 91 (second case).
Boinet and Mesnet, 'Rev. Méd.,' 1835.
James, 'Lancet,' 1842–3, vol. i, p. 62.
Scott, 'Lancet,' 1843–4, vol. i, p. 29.
Beauvais, 'Bull. Soc. Anat.,' 1845, p. 73.
Lowdell, 'Med.-Chir. Trans.,' 1846, vol. xxix, p. 253.
Blondeau, 'Bull. Soc. Anat.,' 1849.
Ogle, 'Path. Soc. Trans.,' 1850, vol. iii, p. 375.
Charcot, 'Mém. Soc. de Biol.,' 1852, t. iv, p. 101 (a valuable thesis and collection).
Pize, 'Bull. de la Soc. Anat.,' 1853, p. 76.
Perrin, 'Compt. rend. Soc. de Biol.,' 1853, t. v, p. 155.
Jones, 'Path. Soc. Trans.,' 1854, vol. v, p. 298.
Birkett, 'Med. Times and Gaz.,' 1855, vol. i, p. 161 (quoted by Babington and many others).
Budd, 'Med. Times,' 1859.
Wunderlich, 'Archiv für Physiol. Heilkunde,' 1858, t. ii, p. 283.
Guerbois and Pinault (quoted by Davaine).
Quain, 'Med. Times and Gaz.,' 1860, vol. i, p. 495.
Bright, 'Abdominal Tumours,' 1860, p. 40, case viii (probably Birkett's).
Habershon, 'Path. Soc. Trans.,' vol. xi, p. 155.
Hughes, 'Med. Times and Gaz.,' 1861, vol. ii, p. 323.
Maunder, 'Lancet,' 1864, pt. ii, p. 351.
Bryant, 'Path. Soc. Trans.,' 1866, vol. xvii, p. 278; 'Lancet,' 1865, vol. ii, p. 589.
Spence, 'Edin. Med. Journ.,' 1865, vol. xi, p. 265 (full account in 'Lectures on Surgery').
Dolbeau, 'Gaz. Hôp. de Paris,' 1867, p. 276.
James, 'Austral. Med. Journ.,' Melbourne, 1868, vol. xiii, p. 183.
Lansdown, 'Lancet,' 1871, vol. ii, p. 677.
Wickham Legg, 'Path. Soc. Trans.,' 1874, vol. xxv, p. 155.
Butreuille, 'Bull. Soc. Anat.,' 1878, p. 265.
Zichy Worniarski, 'Aust. Med. Journ.,' 1881, p. 494.
Hern, 'Aust. Med. Journ.,' 1880, p. 59.
Tillaux, 'Bull. Soc. Chir.,' 1883, t. ix, p. 143.
Millet, 'Bull. Soc. Chir.,' 1884, t. x, p. 551.
Whitcomb, 'Aust. Med. Journ.,' Oct. 15th, 1885, p. 453.
Hurry Fenwick, 'Path. Soc. Trans.,' 1886, vol. xxxvii, p. 317; vol. xlii, p. 201.
Duplay, 'Arch. de Méd.,' Paris, 1887, vol. i, p. 732.
Walther, 'Progrès Méd.,' Paris, 1887, vol. vi, p. 78.
Carson Fisher, 'Intercolon. Med. Cong. Austral.,' 1889, p. 618.
Fairbank, 'Clin. Soc. Trans.,' 1890, vol. xxiii, p. 224.
Legrand, 'Thèse de Paris,' 1890.
Bennett, 'Lancet,' May 31st, 1890, p. 1180 (oral communication).
Lunn, 'Brit. Med. Journ.,' 1890; 'Path. Trans.,' vol. xlii, p. 198.
C. J. Bond, 'Brit. Med. Journ.,' 1891, vol. i, p. 795.
Tuffier, 'Congr. Franc. de Chir.,' 1891, p. 569.
James, of Melbourne, 'Path. Soc. Trans.,' vol. xlii, p. 212 (oral communication).
Westhoff, of Greifswald, 'Ann. Surg.,' pt. 2, vol. xvii, p. 242.
Vincent, of Algiers, 'Soc. de Chir.,' 1892, vol. xii, p. 21 (quoted in 'Internat. Centralbl. Harn-Organ,' Bd. iv, Hefte 6, 7.
Hurry Fenwick, case iii, 'Internat. Clinics,' vol. iv, 3rd series, p. 233.
Sawkins, 'Austral. Med. Gaz.,' Nov., 1893.
R. Harrison, 'Med.-Chir. Trans.,' 1895, vol. lxxviii.

Dermoid Cysts of the Ovary breaking into the Bladder.

There are a few cases on record which afford grounds for believing that true dermoid cysts of the bladder exist. These will be dealt with in their proper section. The greater part of the cases of so-called dermoids of the bladder do not, however, on careful scrutiny appear to fall into this category, but are examples of a suppurating dermoid situated in the

Fig. 18.—Dermoid cyst of ovary, marked by a vertical slit and surmounting bladder. (Pincus.)

neighbourhood of the bladder breaking into that viscus, and discharging its contents into the urinary passages. This usually occurs in females.

The disease known as "Pilimictio," so carefully considered by Rayer, and later on by Broca, has been conclusively shown

to be frequently due to dermoid cysts of the ovary opening into the bladder. But males have also been known (Broca, O'Neill) to pass hair in their urine. Probably in males the extra-vesical origin of the hair is due to a dermoid cyst in the urachus or about the sigmoid. I have seen such cysts in both these situations.* The most characteristic case of dermoid cyst of the ovary breaking into the bladder, treated on modern surgical principles, is one which came under the care of Prof. Czerny, of Heidelberg, and is fully reported by Dr. Ludwig Pincus.

Frau K—, æt. 27. After the birth of her first child the urine became milky; and after the second child was born, flakes of

Fig. 19.—Dermoid cyst of ovary laid open, showing teeth and hair. (Pincus.)

pus appeared in the secretion. Above the symphysis was found a fluctuating roundish tumour. It reached almost to the umbilicus, and was tender on percussion. Catheterisation evacuated almost pure stinking pus if the tumour was pressed upon. The urethra was dilated, and Prof. Czerny examined the interior of the bladder. A communication between the bladder and the elastic swelling was detected

* Cf. Rayer, 'Mém. de la Soc. de Biologie,' 1850, p. 221 (5 cases); Broca, 'Bull. de la Soc. de Chir.,' 1868, p. 260.

and enlarged, and a quantity of stinking pus evacuated. The tumour thereon diminished in size. Subsequently large drainage-tubes were inserted through the urethra into the abscess sac, and the result was temporarily satisfactory. The tumour reappeared in the course of time, and all the vesical symptoms returned. Abdominal section was performed, and the tumour was found attached to the upper and back part of the bladder (Fig. 18). The omentum was firmly attached to it. The tumour was removed, and with it the channel of communication between it and the bladder. The wound in the bladder wall was sutured. The patient recovered.

The cyst was a dermoid cyst of the ovary; it contained hair, and had two teeth embedded in it (*b*, Fig. 19).

Literature.

Perforation of the Bladder by Ovarian Cysts which had not the Character of Dermoid Cysts (Pincus).

Baker, "Exp. des diff. moyens usit. dans le traitement des hydropsies," 1705. Cf. Gallez, 'Histoire des Kystes de l'ovaire,' 1873, p. 135.

Bennet, 'Schmidt's Jahrb.,' lxv, p. 347. Cf. 'Monthly Journal,' Feb., 1849.

'Bulletin de thérapeutique,' t. xxxvi, p. 235, March 15th, 1849.

Cahen, 'Berl. klin. Wchnschr.,' 1869, No. 51.

Clay, 'Trans. Obst. Soc. Lond.,' 1860.

Conrad, 'Correspondenzbl. f. schweiz. Aerzte,' 1874, No. 21.

Denmann, 'Med. and Phys. Journ.,' ii, 20.

Emery and Lisfranc, 'Rev. méd.,' 1827, t. i, p. 362. Cf. 'Arch. gén. de méd.,' t. xiii, 1827, pp. 295, 296.

'Gaz. d. hôp.,' 1864.

Harding, 'Lancet,' 1861, p. 401.

Holzbeck, 'Schmidt's Jahrb.,' 1858, vol. cxx.

Morelle. Cf. 'Gallez,' p. 154.

Nepveu, 'Ann. de gynéc.,' 1875, t. iv, p. 14.

Thirial. Cf. 'Gallez,' p. 147.

Tillaux, 'Bulletin de la Soc. de Chir.,' x. 'Vgl. Virchow-Hirsch Jahresbericht,' 1879, ii, 570.

Perforation of the Bladder by Ovarian Dermoids.

Achard, 'Arch. gén. de méd.,' 1886.

Lannelongue and Achard, 'Traité des kystes congénitaux.'

Blackmann, 'Am. Journ. Med. Sc.,' 1869, p. 113, No. 49.

Blich-Winge, 'Schmidt's Jahrb.,' vol. cl, p. 294.

Boivin and Dugès, 'Traité pratique de maladies de l'utérus et de ses annexes,' t. xi, p. 580.

Delarivière, Lebert in Ziemssen's 'Handbuch f. Path. u. Ther.,' Bd. ix, 2, S. 278, 279. Cf. 'Journ. de méd. et de chir. de Vandermonde,' 1, x, p. 516, Jan., 1759.

Delpech, vgl. Lebert a. a. O. Cf. 'Clin. chir. de Montpellier,' Paris, 1828, t. ii, p. 521.

Fuller, 'Path. Soc. Trans.,' vol. xxi, p. 273.

Gluge, 'Schmidt's Jahrb.,' vol. cxlix, s. 175. Cf. 'Presse méd.,' 1870, vol. xxii, p. 42.

Greenhalgh, 'Lancet,' Nov. 22, 1870, vol. ii, p. 741.

Hamelin, vgl. Lebert a. a. O., 'Bulletin de la Soc. de l'École,' 1808, No. 4, p. 58.

Larrey, 'Arch. gén. de méd.,' 1842, 3rd ser., t. xv, p. 510. Vgl. Spencer-Wells, 'Krankh. der Eierstöcke,' Uebersetzt von Grenser, Leipzig, 1874, S. 49.
Lebert, 'Prager Vierteljahrschr.,' 1588, Bd. iv, S. 37 ff.
Marshall, vgl. Lebert a. a. O.
Mayer, 'Monatsschr. f. Geburtsk.,' Bd. xxi, S. 252.
O'Brien, 'Dublin Journ.,' March, 1834, vol. v. Vgl. 'Monatsschr. f. Geburtsk.,' vol. xxi, s. 255.
Philipps, 'Med.-Chir. Trans.,' vol. ii, p. 427.
Pincus, 'Deutsche Ztschr. f. Chirurgie,' Bd. xix.
Ruge, 'Verhandl. der Gesellsch. f. Geburtskunde in Berlin,' 1846, vol. i, p. 172.
Seutin, Billroth, 'Handb. der Frauenkrankh. Abschn.,' vol. ix, s. 157 (Winckel). Cf. 'Annales de méd. belge,' Dec., 1838. Cf. Gallez a. a. O., S. 147.
Ulrich, 'Monatsschr. f. Geburtsk.,' March, 1856.
Vidoni, 'Annal. Univers. Milano,' 1865, vol. cxcii. Vgl. Gallez a. a. O., S. 154.
Waelle, vgl. 'Dissertation,' S. 17 ff.

CHAPTER III.

PRIMARY TUMOURS OF THE BLADDER.

MANY classifications, all more or less elaborate, of the primary tumours of the bladder are to be found in the literature.* I have followed that arrangement which seems to best fulfil the pathological requirements of the subject, and to be in accordance with our present state of knowledge concerning the causation of sarcomata. Infective granulomata as we at present know them are, of course, excluded.

GROUP I.—*Epithelial Tumours.*

Benign	Papillomata. Adenomata.
Malignant	Malignant papillomata. Epitheliomata. Carcinomata.

---

* The best of these is that adopted by J. Albarran, 'Les Tumeurs de la Vessie,' 1891, p. 44:

Tumeurs nées de l'épithélium	Groupe atavique.	Type allantoïdien. (Papillomes.)
	Groupe vésical adulte	Type de revêtement commun. (Papillomes.) Type de revêtement à cellules claires. (Papillomes.) Type glandulaire. (Kystes, adénomes.)
	Groupe atypique.	Épithélioma: 1°. Lobulé ou tubulé. 2°. Cylindrome. 3°. Carcinoïde. 4°. Réticulé. 5°. Myo-épithéliome.
Tumeurs nées du tissu conjonctif	Groupe atavique	Sarcome. Myxome. Fibro-myxome.
	Groupe adulte .	Fibrome.
Annexe aux tumeurs conjonctives .		Angiomes.
Tuméurs nées du tissu musculaire	Groupe atavique.	
	Groupe adulte .	Myôme adulte.
Tumeurs hétérotopiques	Kystes dermoïdes.	
	Épithéliomas cornés.	
	Chondromes.	
	Rhabdomyômes.	
Appendice . .	Kystes hydatiques.	

BOSTON MEDICAL LIBRARY
FEB 15 1921

GROUP II.—*Connective-tissue Tumours.*

Benign...	...	... Myxomata. Fibromata. Myomata. Angeiomata.
Malignant	...	... Sarcomata.

GROUP III.—*Dermoids.*

BENIGN EPITHELIAL TUMOURS.

1. *The Papillomata.*

Neither museum nor cystoscopic knowledge warrants us in limiting the term papillomata merely to "villous* tumours" of the benign type. It is true that the succulent mucous membrane of the bladder, like other soft squamous-celled surfaces, evinces a special tendency to produce villous processes, and it is probable that this is the reason for the villus-covered growth being the most common of all tumours met with in the bladder. It is, however, a mistake to expect all papillomata to be covered with typical villous processes. The villous process may be so short, so uniform in length, and so compactly arranged as to be unrecognisable, and the surface will then appear almost smooth; a little separation being necessary to show the leaflets. Again, many papillomata vary in the aspect of their covering in different parts of their surface. I have often seen smooth surfaces and typical villous processes co-exist on the same growth. Moreover I have met with patches of flat warty surface growth upon villous papilloma, identical in appearance with the hard wart on the hand. This smooth variety is not included by many writers, by some it is not even noticed, yet probably it is merely an advanced stage in the life-history of a villous papilloma. The consistence or framework of the benign papillomata also varies greatly. By prolonged irritation, by traumatism, or even in the progress of years, the connective-tissue basis

* The literature of tumours of the bladder is rich in the names which have been suggested for the various forms of growth. Of this diversity of names the first tumour engaging our attention is a good example—the so-called "villous growth." The christenings and re-christenings of this familiar warty tumour have been many and numerous. The term "villous" is certainly, of all its aliases, the most objectionable, for, as will be shown, large numbers of vesical neoplasms acquire a villous covering—*e. g.* fibroma, sarcoma, epithelioma, carcinoma. Thence a villous growth may denote any form of tumour, provided its surface is covered with the so-called villous processes. "Papilloma" is the term which seems best adapted for the innocent warty growth, with the qualifying prefix of "villous."

of the growth thickens and becomes more tough and fibrous; at the same time the papilloma becomes balder of processes, those villous processes which remain are short and thick, and become more or less buried in epithelium. Many of the so-called fibromata are, I suspect, dense papillary growths, and not what is understood by the term fibromata.

Papillomata may be divided into—

Villous papilloma.
Fibro-papilloma.

Although both these probably are stages in the same papillary growth, it will be convenient for clinical purposes to consider them separately.

(1) *The Villous Papilloma. (Fimbriated Papilloma—Thompson); Zottenpolp.*

The appearance of this growth, which is best seen when it is viewed in water, is characteristic.

(*a*) *The Surface.*

The processes or "villi" which clothe the surface of the tumour are often of extreme tenuity, and resemble chorionic villi. Even after death, when they have lost their turgidity, they sway freely about, influenced by every artificial current of the fluid with which they are bathed. Their appearance causes the growth to resemble a sea-anemone, such as the *Tugartia rosea,* whose delicate fringe-like tentacles swing about in search of food, or, as Sir H. Thompson has so aptly conceived it, "like slender-leaved aquatic plants in deep water." On being raised from the fluid medium the processes collapse, and the tumour forms a shapeless mass like a piece of soaked velvet; or, if the processes be long, like a clump of wet cotton wool.

The individual villi vary greatly in length, size, and shape. Some are remarkably long, 1½ to 2 inches (frontispiece), others are stunted. The shorter are usually the thicker. Some villi are cylindrical like tentacles of an anemone, others branch and re-branch, taking on a dendritic arrangement. The point of a villus also varies. It may terminate abruptly and be clavate, or taper to a point. It may bifurcate, trifurcate, or even digitate, and terminate in many branches like a pollard tree. Some villi are thin and flat, and acquire a

long leaf-like form. This foliaceous variety forms a very compact villous papilloma. The short, squat, densely packed villous processes are more commonly met with than the longer and more delicate villi. The long and slender variety, if unaffected by secondary changes, present an appearance of great beauty under the electric light of the cystoscope, for the long thin finger-shaped processes of translucent greyish material are seen to be centred with a clearly defined red capillary. They are most usually met with in younger patients, æt. 20—30.

Well-marked simple villi are to be found in most museums; No. 3694, R.C S.Mus. (*vide* Plate II); 41A, St. George's (*vide* Plate IV, fig. A), and in Norwich (frontispiece), are especially characteristic and beautiful.

Not infrequently in multiple growths the individual villous processes at one part of the bladder will differ in shape from those at another. At one part of the bladder the tumour may be quite bald and gelatinous, or it may be clothed with a variety which is essentially different in appearance from that covering another portion. This is especially evident in cystoscopy.

If fatty infiltration, or necrosis, or phosphatic deposition have taken place, the villi will be changed, becoming white or greyish, or speckled with white lines. Sometimes the tuft resembles the matted wool of an unshorn sheep; others are nodose, like the thongs of a knout (Middlesex Hospital, 1745).

(*b*) *The "Framework" or "Core" of the Tumour.*

The body of the tumour consists of delicate connective tissue in more or less abundance. Some tumours seem to be merely villous processes placed upon a thin wick of connective tissue, others are firmer. The consistence varies with the sessility of the growth, with the age of the patient and the inflammatory influences to which it has been exposed. This central scaffolding contains many fibres of smooth muscle, which arise in the submucous layer.

(*c*) *The "Attachment" or "Base" of the Growth.*

The growth may be attached to the surface by a pedicle, which may vary in thickness from a mere thread to that of a quill; or the stalk may be a fold of mucous membrane, more

Tufted, shreddy, flocculent, villous papilloma springing from area of right ureteral orifice, from a patient æt. 65 (Sir Everard Home's case, R.C.S. Museum, 3694).

or less extended. In other cases the growth arises without any trace of pedicle or stalk, and it is then termed sessile.

The villous processes may spring directly from the mucous membrane, singly and unsupported by any basal core; collections of such processes may cover larger or smaller areas of the bladder, and give rise to symptoms almost precisely similar to those induced by the villous papillomata. It will be as well before discussing the latter in detail to briefly allude to this condition.

Villous Alteration of Mucous Membrane.

Isolated villi placed closely together are often found converting large areas of the bladder into velvety patches, and causing it to resemble the mucous membrane of small intestine in appearance and to the touch. The villi which effect this distribution are usually short, thick, and unbranched. They are thicker and more conical than any of those found covering definite tumours.

I have met with this condition on many occasions, not only in the post-mortem room, but also clinically. In one case I removed a bladder in the routine of an autopsy. Five grape-pip sized pedunculated growths were found springing from the trigone, and a villous carpeting covered the posterior wall, stretching in large patches towards the apex. It was very dense. The surface felt like wet Utrecht velvet.

I believe this condition to be induced by direct irritation of the surface, for I have usually found it in bladders which have been subjected to prolonged mechanical or chemical stimulation. This is well illustrated by a case shown at the Pathological Society by Dr. Rake, of Trinidad.* A straw 4½ inches long, covered with phosphates, had been found in the bladder of a leper patient. One end of the straw projected into the prostatic urethra. Situated at the apex of the viscus, against which the other extremity of the straw would continually impinge, was a patch of villous carpeting covering an area the size of a sixpence. Signs of cystitis were of course present.

In the Glasgow Royal Infirmary (Ser. vii, 64) there is a bladder showing a single patch of villous change about the size of a sixpenny piece towards the upper part of the posterior wall. A large oval uric acid stone was found in this

* 'Path. Trans.,' vol. xxxvii, 1886, p. 545.

bladder after death, and its upper rim probably rested upon this diseased patch, and as probably induced it.

In the Hunterian Museum (4347) there is the bladder of a man æt. 77, whose prostatic retention used to be relieved by a "catheter en demure." Towards the apex of the bladder, where the tip of the catheter would press in the contracted state consequent upon the catheterism, there is a patch of villous change the size of a sixpence.

In Norwich there is a beautiful specimen of an hour-glass bladder, the surface of the upper third of which is entirely transformed into a villous condition. The patient, who was a boy, was sixteen, and had been thrice cut for stone.

It is possible that a single patch is liable to spread, and its villous constituents to increase in length. Thus in the Manchester Museum ($\frac{61}{134}$) the entire mucous membrane of a female bladder, except a patch or two of healthy mucous membrane, shows a fleecy villous surface. In Birmingham (d. 7, Queen's College) the entire posterior wall of a bladder is similarly affected.

The soft parts and pelvis of a male æt. 61, who had had extroversion of the bladder,* was recently shown at the Pathological Society. The mucous membrane of the bladder was greatly hypertrophied and markedly villous. The skin of the stumpy penis and scrotum was also thickened, and the papillæ were hypertrophied from the constant irritation of the decomposing urine.

Out of 60 cases of villous papillomata which I have collected from the various museums, 12 specimens exhibit villous surface.

In 4 of these the patch is small and towards the apex, the co-existing trouble being stone in 2 cases, and a catheter and a foreign body in the other 2.

In 5 the patch was on the trigone. In 3 it carpeted the posterior wall.

Clinically.—I believe this condition to be somewhat more frequent clinically than it is usually supposed to be. I noticed a small patch around a depressed scar of a sinus which had formerly been the track of an extra-vesical abscess.† I have met with it co-existing with calculus in a patient æt. 47, sent me by Surgeon-Major Keogh.‡

The most marked example, however, came under my notice

* 'Path. Trans.,' vol. xlii, 1891, p. 215.
† Author, 'Cardinal Symptoms,' Case 76, p. 237.
‡ Ibid., Case 84, p. 264

quite unexpectedly, for the patient had never passed blood. A woman was transferred to me from Dr. Gilbart Smith's ward suffering from left renal colic. Her urine contained a good deal of pus and albumen. The specific gravity was 1010. Casts were present. Her legs had swelled. I examined the bladder to estimate the rapidity of the left ureteral efflux. To my surprise a patch of dense, flat, warty growth was seen in the posterior and upper wall (upper zone). Each individual projecting villus was conical, very short and thick. There had been apparently no cause for its appearance. The vessels of the base of the bladder were dilated and very numerous. The sheen of the epithelium had become dulled. Beyond this nothing was abnormal.

These little patches may be seen at the orifices of hernial protrusions of the vesical mucous membrane, at the edges of post-prostatic pouches or depressions which have held residual urine for some time, upon the upper rim of the urethral orifice, and upon prolapses of the mucous membrane of the ureter. They form a distinct pitfall to the inexperienced cystoscopist, who diagnoses a villous papilloma by sight, and cannot find it by touch.

The importance of recognising that such sessile villous areas may be met with is well exemplified in a case which came under the care of Keyes, of New York, after perinæal cystotomy had been twice performed without relief, and without the discovery of the cause of the bleeding. Keyes opened the bladder supra-pubically, and detected the villoid surface, not by touch, but by sight. It was scraped and the patient cured.*

On reading the many futile digital explorations for vesical hæmorrhage, suspicion is aroused that instead of "no cause for the hæmaturia being found," a villus-covered area might have been undetected in some cases at least. The suspicion that this condition is caused by irritation is somewhat strengthened by the frequency with which such patches coexist with carcinomatous or other tumours.

* 'Journ. Genito-urinary Diseases,' July, 1887, p. 247.

*Detailed Characters of the Villous Papillomata.**

The villous papilloma is generally encountered in the form of a distinct tumour or separate tumours. It is of some practical importance to consider the position in the bladder affected by such outgrowths, the character of their attachment to the surface, and the size to which they may attain. Lastly, it will not be uninteresting to hazard a conjecture concerning the causes for their position and multiplication.

Examination of single tumours affords the best basis for reliable information regarding the above points.

(A) *Position.*—Single villous papillomata are most often found in the lower zone or base of the bladder (89 per cent. museum work, 98 per cent. clinical). They are most usually found in the immediate neighbourhood of the ureteral orifices (70 per cent. museum, 90 per cent. clinical); so nearly attached are they to these orifices that it often appears as if they sprang from the very lips or margins. But this is rare. Still rarer is it for the everted mucous membrane of the ureter to be the site of a papilloma, although carcinomata† have been known in this position. In a patient sent me by Dr. Little, of Nelson, suffering from a large stone impacted in the lower part of the ureter, I removed supra-pubically a prolapse of the ureter. The protrusion was crowned with a tuft of villous growth.

I should hazard a suggestion that the most common origin is just behind and to the outer side of the orifice. In cystoscopy also I have not infrequently seen the jet of urine as it issues from the ureter throw the superjacent villi upwards as they overhung the mouth of this opening. The right ureteral orifice was affected almost as frequently as the left in my clinical work.‡

The trigone itself is rarely occupied by a single villous papilloma, and it also appears to be but seldom encroached upon by the invasion of papillomata in its neighbourhood (seven cases). In fact, I would submit that *villous papillomata*

* The statements made under this heading are based on an examination of fifty museum specimens, and on the cystoscopy and operation of the first fifty cases of this form of benign growth which I have had under my care.

† In one case (1924, London Hospital) a malignant papilloma has grown from the mucous membrane of the ureter, which has slightly prolapsed into the bladder.

‡ Clinical work:—In 23 instances the papilloma was at the right ureteral orifice, and in 22 at the left; in 4 instances it was at the base and side of trigone. Museum work:—At the right ureteral orifice, 13 cases (trigone affected to a lesser degree in 6); at the left ureteral orifice, 8 cases (trigone encroached upon, 1 case); at the urethral orifice, 0 case; from the inter-ureteral bar, 3 cases; from the trigone, 2 cases; from the middle zone, 3 cases; from the upper zone, 1 case.

hardly ever originate upon the trigone, but they invade it from the adjoining areas. The trigone is perhaps the only "enclosed space" in the bladder without the power of originating villous papillomata.

This conclusion receives some support from the fact that the structure of the trigone is especially dense. It has not the laxity of tissue necessary to produce a soft pedunculated mass, and its very density seems to debar it from forming those delicate villi so characteristic of the disease. Thus, when invasion by circumtrigonal growths takes place, a stunted villous carpeting is generally produced.

The inter-ureteral bar is not often affected (6 per cent.).*

Among museum specimens there are only three bladders in which a *single* villus-covered papilloma has sprung from the mucous membrane of the urethral orifice, and clinically they are rare. In one case (Case 61) on which I have operated the tumour was removed from the extreme neck of the bladder.† This fact is of importance when we consider the symptomatology of this growth.

It is rare to find large *solitary* villous papillomata on the anterior surface. I had an opportunity of examining a remarkably fine specimen, however, in Bonn. It was found in a horse's bladder. It was sessile, and equal in size to a man's (full-sized) fist. Clinically there are few recorded. Cystoscopically a villous papilloma on the posterior wall looks as if it sprang from the anterior, and probably a few mistakes have thus occurred.

When the growths are multiple, one occasionally finds a tuft on the anterior wall (cf. Hunterian, 3694). In villous carcinoma nothing is more common than to find malignant and benign tufts on the anterior wall. These probably are excited here by contact inoculation. The positions of multiple growths are too irregular, and apparently too haphazard, to enable us to draw sound practical conclusions.‡

* Three instances occur in museums. In one it is a mere fringe (467, King's), whilst in the other two a fair-sized tumour has been formed from ½ inch in diameter (Hunterian, 3695) to a small Tangerine orange (Queen's College, Birmingham). Three instances occurred in my clinical work.

† In cystoscopy there is sometimes a fringe of delicate villi seen on the upper segment of the orifice.

‡ Site of the principal tumour or tumours in multiple growths:—Right ureteral orifice, 4 cases; left ureteral orifice, 3 cases; both orifices, 2 cases; over or at side of urethral orifice, 3 cases; inferior zone, 2 cases; middle zone, 2 cases; upper zone, 1 case; general, 5 cases. Therefore in 5 cases out of 23 the tumours were so generally placed as to afford no definite data of position; 14 cases out of 22 were found in the inferior zone in the neighbourhood of the trigone.

I have generally found them arranged along the outer limbs of the trigone, and scattered over the lower posterior wall.

(B) *Size of Single Papillomata.*—Like growth elsewhere, there is no law governing the increase in the size of the papillomata. We are therefore quite unable to say how long any given tumour has been in existence, or how quickly it will grow if left alone. The luxuriance of any particular villous papilloma does not depend upon the duration of its existence, or its position near the best blood-supply.* The largest I have removed filled a 6-ounce measure glass, and its history only extended over two years. The next largest filled a 4-ounce measure, and the duration of its symptoms was one year; whilst, on the other hand, I have removed small growths which have been known to exist for many years—one for twenty years, and its size was that of a walnut. My own belief, based on cystoscopy, is that cystitis and the traumatism of sounding, increases the size of the papilloma by inflaming its base.

On turning to museum specimens, single growths are met with which have been known to exist for sixty years (St. George's Hospital, 41B). Probably each year† adds a slight increment to the actual bulk of a *purely innocent* tumour. It is otherwise, of course, when the base is taking on malignant action; and very luxuriant growths, even when demonstrated microscopically to be innocent, are suspicious.

Taking the museum specimens as a gauge of the type to which these growths may attain when undisturbed by the operator, it will be found that they vary from a pea-sized tuft to a large Tangerine orange sized mass (King's College, 465). The average size is that of a walnut.

The size of the various tumours in a bladder affected by multiple growths varies greatly, and it is not uninteresting or unimportant to notice that while one attains moderate dimensions, the others remain small. This is more especially the case in the pedunculated variety.‡

(C) *The Character of the Attachment to the Surface.*—A villous papilloma may, as before remarked, rise from the

* The electric cystoscope used after operative removal demonstrates that villous growths vary very greatly in their rapidity of growth.

† The effects of the duration of time upon the multiplicity of these tumours is discussed under the head of "Multiple Villous Papillomata."

‡ I might suggest the reason for this is either that the smaller growths are seedlings from the larger and pedunculated tumours, or that one growth dwarfs the remainder, just as obtains in multiple products of the womb. Cf. the varying sizes of the fœtuses in four sacs of the human uterus in Norwich Hospital Museum (Begbie?).

surface as a definite tumour without any neck or pedicle, in which case the tumour is classed as sessile. Should the form of the growth be such as to cause its base to be narrower than its free surface, the term subsessile is employed; whilst those with a more or less constricted stalk or pedicle are grouped as pedunculated. Pedunculation, or a tendency to such, is more commonly met with. In the museums, of 30 single villous papillomata, 11 cases are sessile, 6 are subsessile, and 13 are pedunculated;* whilst in my clinical records 29 were pedicled, 6 had a broadish base and were subsessile, and 15 were sessile.†

In the cases examined in museums, the pedicle varied in length from one sixteenth of an inch to half an inch (King's College, 465), and even an inch (University College, 1500); and in shape from a cylindrical column (Bartholomew's Hospital, 2417) to a flattened membranous attachment (Kiel, 34). The thickness of pedicles may be mere fine strings or threads to half an inch in diameter (University College, 1471 A), and considerable masses of growth can be supported by such attachment. Thus one tumour was the size of a goose's egg (Middlesex Hospital, 1743) another a large Tangerine orange (King's College, 465), and both have very slender stalks, whilst in one case I operated on the tumour seemed to fully occupy the contracted bladder, and on removal it filled a 4-ounce measure glass, and yet its pedicle was the thickness of a goose-quill. It is interesting to note that the larger tumours are more often pedicled than the smaller, that the sessile are nearly always small. The pedunculated variety, moreover, are usually a little posterior and external to the ureteral orifice, whilst the sessile group are along the outer border of the trigone.‡ Perhaps these facts find a part explanation in the effects of the outrush of urine acting on masses which are near the orifice of the bladder; probably the mucous membrane at the bases of the

* That is to say, had the patient's condition allowed of operation, in 19 out of 30 cases (66 per cent.) the growth would have been easily and successfully removed because some sort of a pedicle existed. From my experience of the treatment of the sessile form I am in a position to state that only two out of the thirty are inoperative.

† That is to say, the operator's chance of an easy straightforward case is 70 points in 100 if the patient has not been operated upon before.

‡ The positions in which museum pedunculated villous papillomata are generally found:—Around lips of right ureteral orifice, 7 cases; around lips of left ureteral orifice, 4 cases; border of right side of trigone, 1 case; inter-ureteral bar, 1 case. Thus of 13 pedunculated single villous papillomata the *borders* of the trigonal triangle formed the point or site of origin in all. Among my clinical cases pedunculated tumours affected the right sixteen times, the left eleven times, and the inter-ureteral bar twice.

tumours becomes relaxed and stretched by traction, a pedicle being thus formed. The process of pedunculation must be very gradual, judging from clinical experience. I have known a pedunculated tumour to suddenly fall into and cork the orifice of the female urethra during dancing, no previous symptom of its presence having been noticed.

Multiple Villous Papillomata (Plate III).

Hitherto only those specimens have been considered in which a villous papilloma existed as a single growth. Interesting problems centre round the subject of multiple villous papillomata, and it will be better to consider these at this juncture.

Multiple tumours are only met with in the smaller proportion of specimens stored in museums (30 per cent.); and I believe in practice, when there is no tendency to malignant action, and *where no operation has been undertaken*, multiple growths will be even less frequently encountered. This latter statement is supported by the fact that of fifty cases of tumour of the bladder operated upon by Guyon (Albarran),* only one case of villous papilloma proved multiple. In a collected series of 100 cases in the literature only one case (Southam's) is recorded where more than one villous papilloma was removed from the bladder. In my own list of fifty, in only three cases was more than one growth discovered, and they were sessile. It must, however, be distinctly understood that these three cases had not been operated upon previously—a reservation to which I allude under the heading of the cause of multiplicity (p. 62 [4]).

The Numbers of Multiple Villous Papillomata.

In half the cases of the *presumably benign* multiple papillomata which I examined in the museums the tumours were uncountable; and in the other half the tumours ranged from two to ten in number. In seventeen cases out of twenty the numbers varied from three to twenty-two and more.† It is probable, therefore, that if more than one well-marked villous growth is readily found, others will be co-existing, and a

* Albarran, loc. cit., No. 43, p. 440. Other cases appear, however, in the tables in Albarran's work (Cases 154, 169, 173, 175, 180, 181, 184).

† I estimated them in 11 of the 20 cases :—2 tumours were present in 3 cases, 3 in 3 cases, 4 in 1 case, 5 in 1 case, 8 in 1 case, 9 in 1 case; 22 in 1 case; "many," but uncounted, in 9 cases.

Diffuse villous papilloma (from J. Albarran).

diligent search in operative practice ought to be made for scattered tufts. More careful microscopy of the bases of these growths may demonstrate a certain number to be malignant.

Cause of the Multiplicity.

A correct solution of the problem of the causation of *single* villous papillomata would go far to elucidate the reasons for the appearance of multiple growths. Although the meagreness of our knowledge of the ætiology of tumours of the bladder forbids any decided opinion being expressed upon the subject, yet there is, I submit, some evidence adducible which would tend to show that the single villous papilloma is probably the direct result of prolonged irritation acting upon a mucous membrane prone by heredity or disposition to take on papillomatous formation (cf. "Ætiology"). Why a *single* papilloma should in the majority of cases be the expression of an irritation which is probably applied to the entire bladder, is difficult to understand. Either we must suppose the surface to be only predisposed to growth construction at one particular spot, or that the irritation attains its maximum in one particular position, and therefore excites growth only at this spot. The latter view is perhaps the more tenable, and the following facts may be cited in its favour.

1. Warty excrescences are often found around the vesical orifices of inflamed fistulous openings communicating with the gut, with abscess sacs, or with the skin.

Thus, around the scar of the orifice of an abscess, which, extending from the acetabulum, had burst three times into the bladder of a young man, I found a warty patch covering an area equal to a threepenny piece.* In a lady, sent me by Dr. Valentine Rees of Brecon, there was a distinct warty area around the minute opening of a parametric abscess which had found its way into the bladder on the right side.†

In Specimen 1500, University College, the mucous membrane of the bladder is quite warty around the orifice of a supra-pubic fistulous opening. Sir H. Thompson had tapped the bladder above the pubes, and had inserted a permanent catheter in this case, to relieve obstruction to the flow of urine, caused by a villous tumour.

* 'Cardinal Symptoms,' p. 237; a patient of Dr. Ayling.
† Author, 'Trans. Med. Society,' vol. xviii, p. 75.

2. The character of the mucous membrane in the immediate neighbourhood of some of the villous papillomata is distinctly altered. The surface often assumes an appearance as if it had received the impress of a coarse thimble, and is often papillated.

St. Bartholomew's Hospital, 2418, is a pedunculated leaf-like papilloma, and the surface in its neighbourhood is honeycombed (cf. also Charing Cross Hospital, 825). In some of the large villous papilloma I have removed, the surface on which the tumour fell and habitually rested, was swollen, granular, and reddened; it had lost its sheen of health, and looked a little honeycombed.

In certain bladders where the irritation is applied to the whole surface this papillation is universal. Thus, in a case of extroversio vesicæ of sixty-one years' duration,* the entire surface was covered with villous projections.

3. In the immediate neighbourhood of villous papilloma, isolated patches of sessile or pedicled villous growth may be detected in a small proportion of the cases. Thus 1743, Middlesex Hospital, is a bladder with a goose-egg sized villous papilloma on the anterior wall, and on each side is a small villous tuft, each of the smaller being quite separate from the large growth.† This fact suggests that the smaller tumours are "seedlings" inoculated from the primary growth.

4. Some patients from whom I have removed a single *sessile* villous growth have returned to me after the lapse of two or three years complaining of a recurrence of the symptoms. On cystoscopy, or supra-pubic cystotomy, I have found the mucous membrane of the posterior wall splashed here and there with densish patches of sessile villous growth. Now whether the mucous membrane had been frayed here and there, and the discharge from the operation wound in the bladder had infected these vulnerable parts of the surface,‡ I cannot say, but it certainly gives rise to the suspicion that the operation had diffused the papillomata.

5. The condition of pure villous splashes or tufts in the neighbourhood of a primary growth is seen to the best advantage in cases of villous epithelioma of the bladder, in

* Referred to on page 54.

† Compare 41c, St. George's Hospital; 2418, St. Bartholomew's Hospital; 3679A, Royal College of Surgeons Museum; 1471, 1471A, University College Hospital; Sussex, Guy's.

‡ It is a common belief that blood taken or issuing from a wart on the hand can give rise to similar warts on the same hand.

which presumably the irritation is greater. In many of these, distinct, even large papillomata of the pure and benign type are noticed.*

These facts tend to show, I submit, (1) that multiple villous papillomata are the outcome of prolonged irritation affecting a surface prone to papillary formation; (2) that the irritation may be local, and produced by the primary growth itself affecting the contiguous mucous membrane or a portion of the surface approximated to it in the emptied viscus; (3) that large areas may be transformed as the result of a severe and more diffused form of irritation, applied probably by means of an acrid fluid medium.

The question that at once suggests itself is, what influence has the duration of time upon multiplicity? If the villous papilloma has the power of evoking others, some relation ought to exist between the number of tumours found and the length of time the original growth had existed.

The following case, of eight years' duration, illustrates what might be expected in the course of time. Mr. Harle, of Hackney,† brought a man to me in October, 1888, with painless hæmaturia and a diagnosis of probable vesical growth. A very beautiful "primrose-leaf" villus-surfaced tumour was seen attached to the upper lip of the left ureteral orifice, its long individual leaves swaying apart at each jet of urine propelled from the subjacent opening. Some of the leaves were whitish from loss of blood-supply. Its pedicle appeared to be succulent and *epitheliomatous*. The patient was leaving for Australia in a couple of days, and refused operation. I supplied him with a photograph of a clay and wax model of this growth,‡ and lost sight of him.

In 1896 I heard he was undergoing an operation on his bladder, and I wrote to his surgeon, Mr. Dudley Wright, to let me know if the growth had increased in size. Mr. Wright says, "When I operated, I found not only the growth you diagnosed, but also a smaller one near the opening of the opposite ureter, and also several small villous growths over other parts of the bladder. He is leaving the hospital. (Nov. 4th, 1896)."

A careful and critical examination of museum specimens

* Cf. remarks on this subject, p. 14, *re* Dr. Drew's "Case of a Villous Carcinoma of the Kidney inducing Ureteral and Vesical Villous Papilloma;" also Fig. 15, p. 32, and case.

† Recorded in 'Electric Illumination,' 2nd edit., p. 92, Case 36, present series.

‡ Ibid., photo-print 4.

shows, however, that the influence of time upon the multiplication of villous papillomata is often small.

Thus 41B, St. George's Hospital, is a villous growth, which had probably been sixty years in existence, and it is single. 41A, the same museum, is a single growth of many years' standing.

3697A, R.C.S., has a history of fifteen years; and I have removed a smallish growth which had had symptoms for twenty years (Case 162), and another, symptoms of which had been noticed for seven years (Case 116).

On the other hand, 3696, Hunterian, is a bladder covered with multiple growths, the existence of which had been suspected only eighteen months before death.

There is, therefore, reason to believe that two factors exist in the production of multiple growth: first, a mucous membrane especially prone to papillary growth; and some form of irritation which affects various isolated parts of the surface.

Among the localising agents may be reckoned such causes as the primary growth, a stone (Glasgow Royal Soc., vii, 64), a foreign body, the opening of a sacculus.

Rare Positions for Villous Papillomata.

Villous papillomata, though usually found at the base of the bladder, have occasionally been seen to spring from other zones. These positions may be enumerated here for the guidance of the operator.

A few examples are to be found in museums of definite villous tufts springing from the sides or bottoms of those tiny dimples, depressions, or saccules which form a characteristic feature of the fasciculated or sacculated bladder.

Thus University College, 1471A, is a specimen of multiple villous papillomata; one large growth surrounds the right ureteral orifice, and a few patches are seen posterior to it. In a small but definite hernia is seen a tiny tuft of villous growth (cf. Hunterian, R C.S., 3696).

I have only seen in one specimen a villous papilloma grow in and from the mouth of a distinct pouch in the bladder (St. George's Hospital, 41A). This pouch was situated at the antero-lateral junction in the left median zone, and the growth was the size of a walnut * (Plate IV, fig. A).

* There is some doubt about this specimen; it is labelled malignant. The photographer has reversed the specimen.

Fig. A.

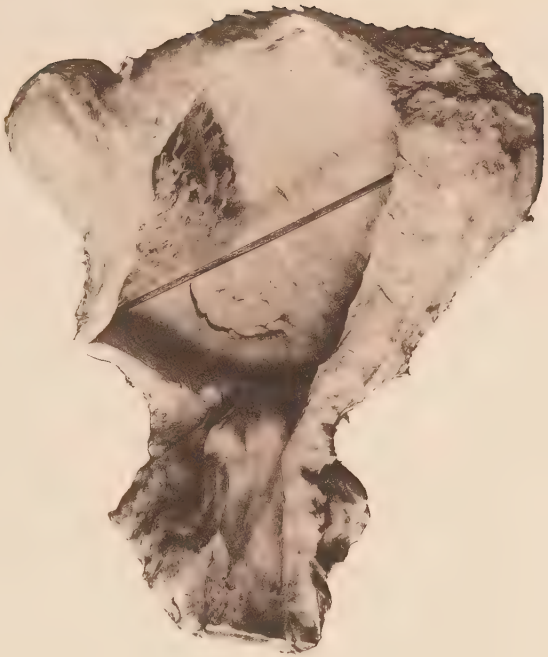

Villous papilloma in a saccule (St. George's Hospital Museum, 41A).

Fig. B.

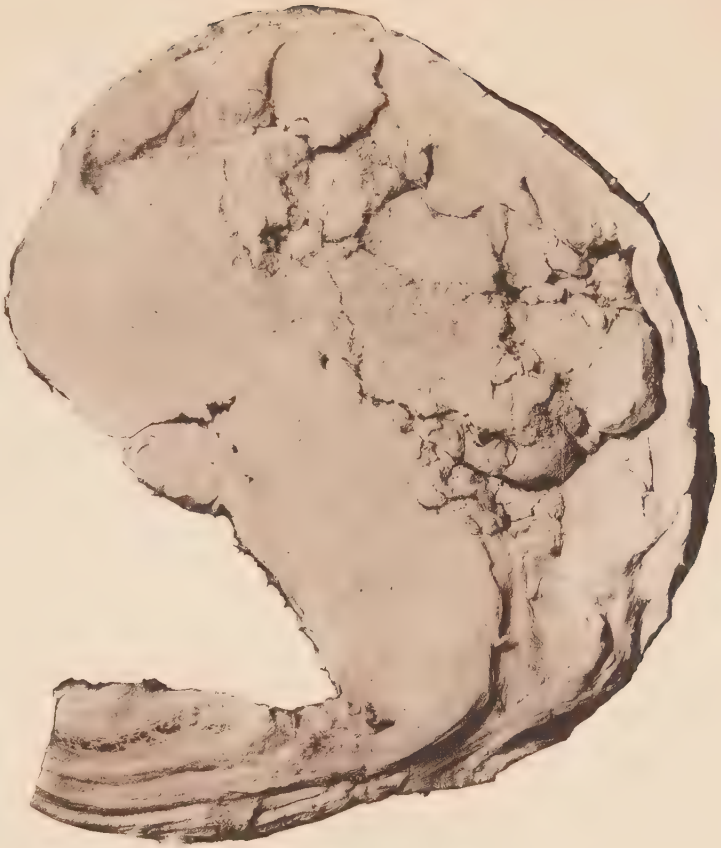

Lympho-sarcoma filling entire bladder. Part of the urethra is shown below (R.C.S. Museum, 3706).

Changes, degenerative or otherwise, in the Villous Papillomata.
(A) *Accidental.* (B) *By disease.*

(A) Injury to the tumour by the violence of spasmodic contractions of the viscus may lead to the breaking off of the tumour if the pedicle be thin. Thus 825 Charing Cross Hospital is the bladder of a man aged 65. The villous growths were attached by such string-like pedicles that many had ruptured, and after death the freed tumours were found loose in the bladder.*

In some instances probably the pedicle gets twisted upon itself by the outflowing stream, and its contained vessels become damaged, hence the growth dies. Or it may happen in some thin pedicles that the blood-supply is only just sufficient for the life of the growth, so that it readily ulcerates or necroses on the receipt of an injury. A slender pedicle was taken advantage of in pre-cystoscopic times, as it is indeed even now by surgeons in search of a diagnosis. Such recommend that a sharp spoon in the shape of a sound be scraped along the bladder wall, in the hope of cutting through the pedicles of any tumour which may chance to be there. Others advocate forcible suction with the fragment evacuator, and others the use of the lithotrite. All such diagnostic practices are to be condemned.

(B) *Disease.*—The entire growth may become necrotic, and drop off free into the cavity. St. George's Museum 41B is a large, coarse, villous mass, $2\frac{1}{2}$ by 1 inch, which had become detached from its site at the right side of the trigone, and was found infiltrated and mixed with much coagulated blood in the bladder of a male aged 81.

The surface of those tumours, which are situated near the urethral orifice, often show signs of ulceration. This is probably from their becoming caught in the orifice or pressed upon by the final effort of the bladder in micturition.

It is interesting to note the difference which sometimes exists between the upper and lower surfaces of a flattish fig-shaped papilloma. The upper, exposed as it is to the urine, is villus-covered, the lower smooth and *bald*, and on tilting up the growth it will be seen that the area of the bladder on which it has been lying is succulent and reddened.

Inflamed bases.—Mr. Targett, who has kindly examined almost my entire operative series with the microscope,

* One of my patients passed a large growth after a long cycle ride (Case 188).

pointed out to me the frequency with which inflammatory changes occur in the bases of villous papillomata. I had previously noted that such bases were thicker than I cared to find, and that they conveyed to my finger the impression that I had to deal with papillomata becoming malignant. I can only trust that the future of such cases will corroborate Mr. Targett's diagnosis. The subject is very difficult, and the microscopist has often to work without the *base* of the growth, hence his prognosis is very seriously handicapped.

Mr. Targett suggests that these inflammatory changes have been mistaken for sarcomatous tissue. Thus 2103[5] Guy's

Fig. 20.—An Inflamed Fibro-papilloma (2103[5], Guy's Museum).

Hospital (Fig. 20) is labelled villous sarcoma. Mr. Targett has proved this to be merely an inflamed fibro-papilloma. Fig. 21, taken from the base of Case 65, shows the inflammatory cells.

Phosphates.—A certain number of villoid growths are incrustated with lime phosphates, &c., caused by the deposition of the salts of urine upon the ulcerated or necrotic patches of their surface (Guy's Hospital 2104[4], London Hospital E.D. 10, Hunterian Museum 3697—4402, Liverpool Royal E. 16). Not infrequently such a deposition demonstrates the activity of the surgeon, who, by sounding for stone induces slight traumatic or septic cystitis, and superadds the misery of cystitis to that of the original disease. But it is not always due

to this cause; often the cracks between the lobules are marked by the white lines of phosphatic deposit, and the urine passed is neutral, clear, and free from any sign of inflammation. It is, however, noticeable that where phosphatic deposition has begun, the surface vascularity of the growth, and therefore its hæmaturial capacity, is lessened; probably the more superficial vessels become plugged.

In carcinomata early phosphatic deposition is the rule, and the white glistening look of the crystals of lime phosphate is

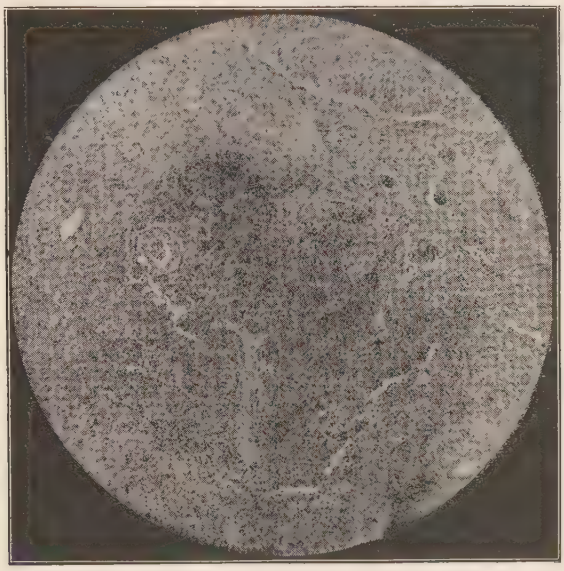

Fig. 21.—Inflammatory area below a villous process. The epithelial lining of the villus is visible at the right hand top corner. (× 80.)

often a valuable indication in determining the character of the growth (compare section on Carcinoma).

Sarcoma.—It is asserted, but on slender grounds, that specimens are met with showing degeneration into sarcomatous growth. Groups of round cells are here and there collected round the arteries; the connective-tissue corpuscles are seen to be proliferating in some of the villi, and the normal transitional epithelium of the villi is here and there replaced by spindle sarcoma cells.*

A very striking case of this transformation is described by

* Cf. cases by Railton, Path. Soc., Manchester, November 9th, 1887, 'Brit. Med. Journ.,' 1168, 1887, ii.

Shattock as taking place in one of Sir H. Thompson's cases. The first pieces of growth * removed had the usual macroscopical structure of vesical papillomata. The external character varied slightly: in some the processes of the growths were finely branched like long compound papillæ; in others the surface was raised in wavy intercommunicating ridges, the free edges of which are but slightly, if at all, cleft. A small solid spheroidal growth, $\frac{5}{8}$ inch in chief diameter, composed of chondro-sarcoma, was also found.

The growth recurred, and nine months after removal the patient died. The bladder was removed, and found to be the seat of extensive disease. There was now a large soft growth about 2 inches in diameter, encroaching upon the cavity from the base. The right ureter passed through the middle of the growth, and was dilated. The exterior of the growth was papillated. The growth was of *round-celled sarcomatous tissue.*†

Carcinomatous Degeneration.

From museum specimens it is obviously impossible to ascertain whether a villous growth became carcinomatous at its base, or whether the growth was a villus-covered carcinoma to begin with.

From my own clinical and cystoscopic experience, I believe if a villous papilloma becomes carcinomatous it does so, not in the free surface as microscopists explain, but in the basal parts of the growths, for I have removed perfect specimens of villous growth with a fine line of hardness at the base as estimated by the finger. Such cases have recurred as non-papillated carcinomata (cf. Malignant Papilloma).

Dr. Paul ‡ mentions a case he had observed with Dr. Alexander; the villous growths, which were at first highly branched, became after each removal more fleshy in character, and when, after more than ten years' hospital treatment, the patient died of uræmia, the papilloma had undergone a

* Shattock, 'Path. Trans.,' pp. 184–5, vol. xxxviii, 1887.

† I quote this, but regard it with great suspicion. It is well known that Sir H. Thompson advocates the removal of the surfaces of growths by chewing them off with forceps. Anyone with the experience of a novice recognises how untrustworthy the *surfaces* of villous growths are for microscopical diagnosis. It is more than probable that the growth was in the first instance a villus-covered sarcoma, and that in it were found cartilaginous nodules (cf. enchondromata of the testicle with sarcomatous admixture, probably being sarcoma of testis with enchondromatous changes).

‡ Cf. Paul's description of Alexander's case, 'Brit. Med. Journ.,' 1884.

malignant change, and was found to be infiltrating the bladder as a carcinoma. "The growth at the part I examined," continues Dr. Paul, "showed no evolution of squamous cells; but that is not a constant condition in carcinoma of the bladder, nor indeed even in the skin. At the same time this evolution of more or less squamous cells is probably constant in papilloma of the bladder, though as the superficial stratum they are very likely to be lost."

Secondary Changes produced by Villous Growth of the Bladder upon the Urinary Tract.

If the tumour be in the neighbourhood of the trigone or neck, and possesses a long pedicle, it becomes sucked into the urethral orifice, dilates the prostatic urethra, and, reacting by its obstructive presence secondarily upon the muscle coat of the bladder, causes first hypertrophy then dilatation of that viscus. The ureters and kidneys suffer in the same manner: a good example of this is seen in a case of Sir H. Thompson's (University College 1500). It is thus described in the catalogue:

"From the posterior part of the trigone near the orifice of the right ureter there has grown a pedunculated villous tumour. The pedicle is thin and stalk-like, and quite an inch in length. The tumour itself forms a villous mass about $1\frac{1}{2}$ inches in diameter. The length of the pedicle is such that the tumour might fall over the orifice of the urethra, and close it like a valve. The muscular wall of the bladder is greatly thickened from hypertrophy; its mucous membrane is thickened and opaque from chronic inflammation; the ureters are both greatly dilated."

This explains, if it needed any explanation, how it is that long-pedicled basal papillomata are the easiest to remove, but are often those which give anxiety subsequently in the course of healing.

To put the matter in another way, I may add that in seven cases out of sixty-one, *thin-walled* bladders were discovered, and in all of these *sessile* growths were found.

Although both ureters are usually affected, they need not be, and are not often equally damaged. Moreover in certain instances only one ureter is dilated, the stress of the pressure having apparently fallen upon one ureter only.

A tumour attached around or in the neighbourhood of the

ureteral orifice exerts tractional pressure upon the mouth of that canal in proportion to its weight or size.* By dragging down the lax mucous membrane it impedes the due efflux of urine from the ureteral orifice, and backward pressure changes in the corresponding ureter and kidney are thereby produced.

A tumour obstructing the ureter by its presence produces first hypertrophy of the channel (St. Bartholomew's Hospital, 2418), then atrophy and dilatation of the walls of the canal, with similar backward pressure changes upon the pelvis and renal structure (cf. frontispiece, and Norwich 508 O.B. 36, ibid. 512, O.B. 42).

Statistics.—Out of thirty-six cases in which the ureters were detected and noted,† in twenty-nine the ureters had suffered more or less from dilatation (80 per cent.); seven only had suffered no change apparent to the naked eye. Of these twenty-nine cases twenty-one had both ureters dilated; in four the right ureter, and in four the left ureter was dilated.

These facts speak volumes for early operative interference, for gentle removal, and for aseptic drainage.

The following axioms may be advanced as a general rule:

1. The longer the pedicle of the growth, the nearer it is to the urethral orifice, the greater the chance of hypertrophy of the bladder and dilatation of the ureters and renal pelves. Such cases will not bear rough sounding or slovenly cystoscopy.

2. The more sessile the growth, the less the chance of renal complications.

Vertical Section through the Wall of the Bladder at the Base of a Growth.

If such a section is made, there will be found in many cases a more or less decided thickening of the submucous tissue. This is doubtless due to the continued strain upon the subjacent tissue if the tumour be pedunculated or subsessile, aided by the increased blood traversing the base of such

* If it be a large growth, and the pedicle contain muscular offshoots from the subjacent tissue, it is not unusual to find a band or two of localised hypertrophy caused by the continual strain of the weight of the growth.

† It is often difficult in bottled specimens which have been long immersed in strong spirit to ascertain accurately the amount of dilatation of the ureters; nay, more, it is sometimes impossible to find the ureteral stump without removing the pickle from the jar, for they are often hidden by the surrounding tissue.

tumour. This slight thickening is of importance. It is also, I believe, an object of suspicion and caution to the operating surgeon. It is important in that it affords him a certain latitude for eradication without destroying the integrity of the wall, and it warns him of the chance of recurrent action being induced at this thickening if it be not removed with the growth; and lastly, it is an object of suspicion, for carcinomatous degeneration often attacks this base, and gives it by infiltration a firm or thickened feel.

Clado affirms that a layer of fatty tissue is to be found at the base of villous papillomata. I cannot as yet corroborate this.

Microscopical Appearances of Villous Papillomata.

On subjecting a fresh, moderate-sized individual villus to microscopical examination, we shall find the greater part of its structure to be made up of many layers of epithelial cells overlying a fine capillary loop (Fig. 22, Case 187, Dr. Hobart's,

FIG. 22.—Three villous processes. (× 50.)

of Cork). The light connective tissue which supports the vessel is often extremely small in quantity, and it can be traced to the base of the villus, and proved to be an offshoot of the submucous tissue. It shows slight fibrillation, and is seen

to contain spindle-shaped cells with round or oval nuclei. A few wandering cells (Waldeyer cells) are to be found at the base of the tumour. Passing into the base of the tumour and spreading therefrom, especially in the larger and heavier pedunculated or subsessile masses, are muscle bundles. These send offshoots into the individual villi, and not infrequently form part of their basis. Like the muscle of Brücke, in the villi of the small intestine, it becomes attached to the basement membrane of the epithelial covering at the very apex of the villus. The capillary loop has a wall of the thinnest.

Of these three constituents the connective tissue is the variable quantity, and the producer of the varieties of villous papilloma. The greater this constituent the coarser the fibre. "Sometimes, however, the epithelium covering the fibres will become very dense, and the whole growth will then seem fleshy, its villous structure being obscured, and simulate and are mistaken for sarcomata."*

In transverse sections just below the attachment of the villi a careless microscopist might, on finding small collections

Fig. 23.—Transverse section of the bases of villous processes. (× 50.)

of epithelial cells, believe that he had to deal with an alveolar carcinoma. These cellular collections are, however, only the

* Paul, "Classification of New Growths of the Urinary System," 'Brit. Med. Journ.,' January 12th, 1884.

accumulation of cells in the intervillary sulcus (Fig. 23, from Case 106) which have been cut across, and one sees the same appearance in transverse sections of the papillæ of the skin and tongue. It behoves us, therefore, to be careful, for should the base of the villus degenerate, as it not infrequently does, into carcinoma, a similar but a greatly increased condition of cellular collections will be produced.

The rule, therefore, in examining the sections of a base of a villus, is to carefully compare vertical and transverse sections.

Fibro-papilloma.

Pathologists and clinicians differ widely as to what may be called a fibro-papilloma. The strict definition of the term designates those warty growths of an innocent character, which possess a papillomatous or papillary surface; the structure of the growth differing from the villous papilloma in being much denser and more fibrous. It is believed by some that fibro-papilloma as thus defined is a common form of vesical tumour. This, I submit, is an error; I have rarely met with it either operatively or in museums. Probably fibromata, sarcomata, and fibro-sarcomata have sometimes been called fibro-papilloma by operators who have not the opportunity of examining the bladders of their patients after death; for it is noticeable that in the descriptions of the operations the tumours are said frequently to be large, and their basal attachments greatly indurated. Now, from my own experience and the various specimens in museums, the fibro-papillomata rarely reach the size of a chestnut, and their bases are soft.

A typical fibro-papilloma has more or less of a smooth surface, though it may be minutely lobulated; papillary processes are either absent or are stunted and thick. The chief part of the growth is made up of more or less dense connective tissue of smooth muscle-fibres and vessels—those constituents originating or being offshoots from the sub-epithelial connective tissue. These tumours are generally small, they affect the same positions as the villous papillomata (in two cases they have been found co-existing with villous papillomata), but are most usually sessile. They rarely attain the size of a chestnut, and are benign, though they are usually covered with phosphates from the irritation they cause. Two cases have occurred in my own practice, both in women.

A typical instance was shown me at Kiel by Professor

Heller, the diagnosis being confirmed by microscopical preparations. The growth was situated on the upper rim of the urethral orifice of a female bladder, and was about the size of a monkey-nut; it was lobulated, warty, and sessile.

A simple example is to be seen in the Hunterian Museum, 3691, and although in the catalogue it is called a mucous polypus, Mr. Targett has shown it to be a fibro-papilloma. The patient died of renal cancer.

Other examples of fibro-papilloma are to be found (R.C.S. 3697, 3697A).

I have known succulent, inflamed rugæ of the bladder to be diagnosed as fibro-papilloma. I have also known such to be operated upon and reported as fibro-papillomata. I was asked to cystoscope one of these cases, and diagnosed "a condition of chronic cystitis with spongy, inflamed rugæ." Subsequently another surgeon operated after demonstrating "the growth" to the onlookers. I obtained the pieces. Mr. Targett examined them not knowing that there was any difference of opinion, and reported the specimen to be merely inflamed mucous membrane. Fig. 24 represents a micro-

FIG. 24.—Inflamed and succulent rugæ mistaken for a fibro-papilloma. (× 80.)

scopical section. The surface is seen stripped of epithelium and the inflammatory focus below and to the right.

Before leaving the subject of fibro-papillomata I should like to draw attention to a group of cases in which the mucous membrane is affected by multiple fibro-papillomata in the form of upraised, sparsely scattered, minute wart-like bodies. The condition seems to bear the same relation to fibro-papillomata that the villous surface change (papilloma *en nappe*) does to villous papillomata.

Five specimens exist in the London museums, and two are in my own collection. The most typical as well as the most beautiful instance is to be found in St. Thomas's Museum, B B 25. The bladder is from a male, and the condition is thus described in the catalogue :—"Situated post-trigonally are sparsely scattered brown-tipped, wart-like, isolated papillæ, $\frac{1}{8}$ inch long." They resemble in appearance the spines on the surface of a ripe prickly pear (*Opuntia vulgaris*). Usually, however, they are in rows, and look like shark's teeth, their apices pointing towards the urethral orifice. The best marked of the shark's teeth-like papillæ is in St. Bartholomew's Hospital, 2372 B. In my own cases the parallel rows of small papillæ form definite and characteristic ridges along the postero-lateral wall.

All seven of the specimens occurred in male bladders; in all the muscle was hypertrophied and the mucous membrane thickened. All seemed the outcome and index of an unusual local irritation.

Adenomata of the Bladder.

Adenomata are extremely rare tumours of the bladder. They, doubtless, form in the small glands near the neck of the bladder. I have been only able to discover two cases, one in museum work and one in the literature (Kaltenbach).*

In the Prague Museum, Spec. 3915, added 1884, there is a small adenoma; it is thus described in the catalogue :—"Two centimetres from the orifice and on the left hand side of the ureter was a small knot, perfectly isolated, about the size of a pea, which, on microscopic examination, proved to be entirely composed of glands. The bladder was removed from a woman æt. 35."

In Kaltenbach's* case a growth was removed from the anterior wall of a woman's bladder (æt. 44). It was the size of a walnut, was subsessile, and had a villous surface.

* Kaltenbach, 'Lagenbeck Archiv,' vol. xxx, p. 660, 1884.

Professor Bostrow examined it microscopically. It is thus described by him:—"The greater part of the growth is made up of glandular structure. The acini are more or less distended, and contain a large amount of transparent mucus and small mucoid corpuscles. These glands open upon the surface of the growth, and the ducts are lined with cylindrical epithelium, which latter is also undergoing mucous degeneration. The acini themselves have a similar epithelial lining. Between the acini is a sparse small-celled connective tissue, very vascular, and containing many dilated lymph-vessels." He pronounces the growth to be a "papillary adenoma originating in a mucous follicle."

BY THE SAME AUTHOR.

ELECTRIC ILLUMINATION OF THE BLADDER AND URETHRA AS A MEANS OF DIAGNOSIS OF OBSCURE VESICO-URETHRAL DISEASES. Second Edition, with 50 Engravings, 8vo, 6*s*. 6*d*.

THE CARDINAL SYMPTOMS OF URINARY DISEASE; Their Diagnostic Significance and Treatment. 350 pp., Illustrated, 8vo, 8*s*. 6*d*.

ATLAS OF ELECTRIC CYSTOSCOPY. With Dr. EMIL BURCHARDT, of Bâle. With 34 coloured plates, embracing 83 figures, Royal 8vo, 21*s*.

NOTES ON A SERIES OF 100 OPERATIONS UPON THE KIDNEY, WITH 91 RECOVERIES. In the Press.

J. & A. CHURCHILL,
7, Great Marlborough Street, London.

MODERN SURGERY OF URINARY DISEASES: An Epitome of the Literature.

WRIGHT & CO., BRISTOL.

5/ net - 200

j 1 yr

17.F.60.
Tumours of the bladder; their p1897
Countway Library BED4938
3 2044 045 680 220

17.F.60.
Tumours of the bladder; their p1897
Countway Library BED4938
3 2044 045 680 220